

# Giant posterior abdominal wall arteriovenous malformation mimicking renal mass: rare images

Arvind Kumar, Manmeet Singh, Satyanarayan Sankhwar

Department of Urology, King George Medical University, Lucknow, Uttar Pradesh, India

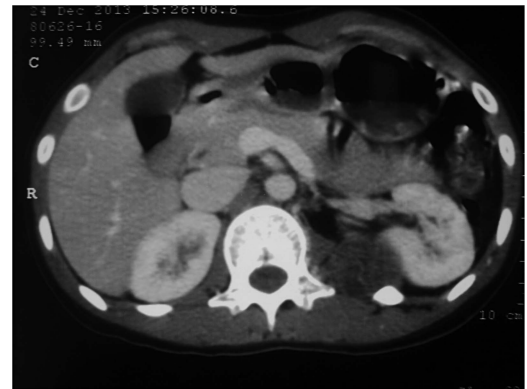**Correspondence to**  
Dr Arvind Kumar,  
drarvindg4@gmail.com

Accepted 11 March 2014

## DESCRIPTION

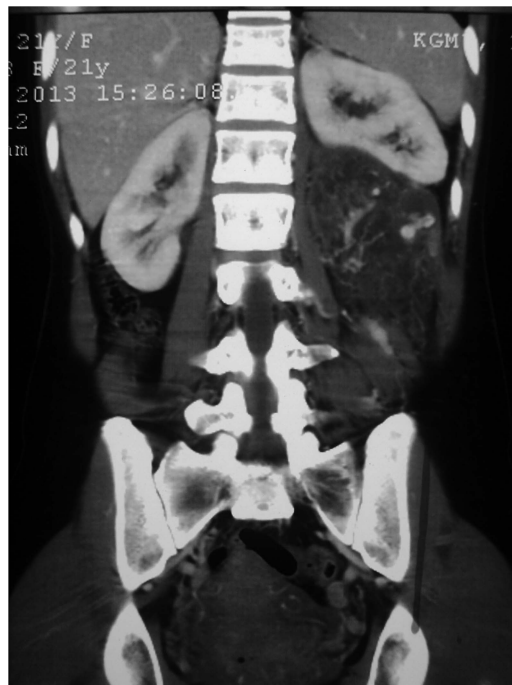Vascular malformations (VMs) are congenital abnormalities of aberrant angiogenesis with reported prevalence of 1.2–1.5%. VMs can be either high flow (eg, arteriovenous malformation (AVM) or arteriovenous fistula (AVF)) or low flow (eg, capillary, venous, lymphatic) type.<sup>1</sup> Head, neck and extremities are the common sites for VMs.<sup>2</sup> Although congenital and often asymptomatic they rarely manifest before adolescence. Pain, bleeding, compressible lump, congestive heart failure and cosmetic appearance are clinical presentations of VMs which may require intervention. Here we report a case of AVM of the posterior abdominal wall presented as flank mass mimicking renal mass.

A 21-year-old unmarried woman presented with left flank fullness and dull aching pain for the past 4 years. She had no urinary symptoms and had normal menstrual cycles. Clinical examination showed an ill-defined, soft, compressible mass in the left flank with palpable thrill and audible bruit. Ultrasound showed dilated vascular channels in layers of posterior abdominal wall. CT angiogram revealed a heterogeneously enhancing soft tissue lesion measuring 7×7×10 cm with multiple

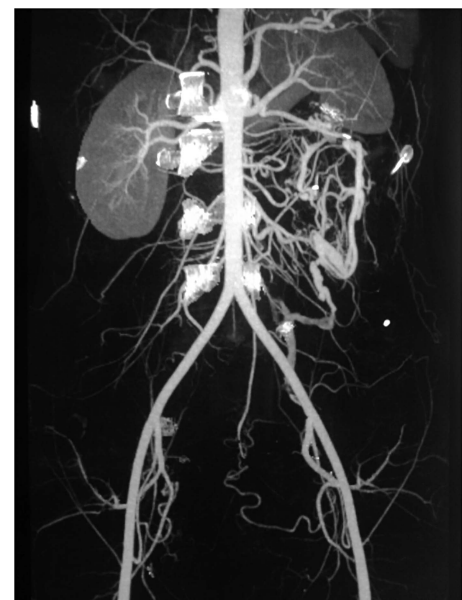


**Figure 2** CT angiogram showing heterogeneously enhancing soft tissue lesion with multiple dilated tortuous vascular channels involving layers of posterior abdominal wall, compressing and displacing the left kidney anteriorly and superiorly.

dilated tortuous vascular channels involving layers of posterior abdominal wall, compressing and displacing the left kidney anteriorly and superiorly (figures 1 and 2). It was fed by all four left lumbar arteries and draining into the left common iliac vein suggestive of AVM (figure 3). She underwent transarterial coil embolisation followed by surgical resection of AVM. The patient is doing well at 2-month follow-up without any recurrence.



**Figure 1** CT angiogram showing heterogeneously enhancing soft tissue lesion with multiple dilated tortuous vascular channels involving layers of posterior abdominal wall, compressing and displacing the left kidney anteriorly and superiorly.



**Figure 3** Showing feeding of arteriovenous malformation from all four left lumbar arteries and draining into the left common iliac vein.



**To cite:** Kumar A, Singh M, Sankhwar S. *BMJ Case Rep* Published online: [please include Day Month Year] doi:10.1136/bcr-2014-204311

## Learning points

- ▶ Vascular malformations are rare congenital malformations of the vascular system that are challenging to diagnose and treat.
- ▶ CT and MRI are the most useful modalities to diagnose and classify this entity.
- ▶ Therapeutic embolisation followed by surgical excision is the best treatment of resectable arteriovenous malformations.

**Competing interests** None.

**Patient consent** Obtained.

**Provenance and peer review** Not commissioned; externally peer reviewed.

## REFERENCES

- 1 Jackson IT, Carreño R, Potparic Z, *et al*. Haemangioma, vascular malformations, and lymphovenous malformations: classification and methods of treatment. *Plast Reconstr Surg* 1993;91:1216–30.
- 2 Dubois J, Soulez G, Oliva VL, *et al*. Soft-tissue venous malformations in adult patients: imaging and therapeutic issues. *Radiographics* 2001;21:1519–31.

Copyright 2014 BMJ Publishing Group. All rights reserved. For permission to reuse any of this content visit <http://group.bmj.com/group/rights-licensing/permissions>.  
BMJ Case Report Fellows may re-use this article for personal use and teaching without any further permission.

Become a Fellow of BMJ Case Reports today and you can:

- ▶ Submit as many cases as you like
- ▶ Enjoy fast sympathetic peer review and rapid publication of accepted articles
- ▶ Access all the published articles
- ▶ Re-use any of the published material for personal use and teaching without further permission

For information on Institutional Fellowships contact [consortiasales@bmjgroup.com](mailto:consortiasales@bmjgroup.com)

Visit [casereports.bmj.com](http://casereports.bmj.com) for more articles like this and to become a Fellow