

Management of chemical burn in oral cavity

Mandeep Rallan,¹ Garima Malhotra,² Neelakshi Singh Rallan,³ Sandeep Mayall²

¹Department of Pediatric Dentistry, Teerthanker Mahaveer Dental College & research Centre, Moradabad, Uttar Pradesh, India

²Department of Pedodontics & Preventive Dentistry, Teerthanker Mahaveer Dental College & Research Centre, Moradabad, Uttar Pradesh, India

³Department of Oral Pathology & Microbiology, Teerthanker Mahaveer Dental College & Research Centre, Moradabad, Uttar Pradesh, India

Correspondence to

Dr Mandeep Rallan,
drmandeepallan@gmail.com

DESCRIPTION

A 7-year-old boy reported to the department of pedodontics and preventive dentistry with the complaint of attached lower lip to the lower gums, difficulties in speaking, eating hot and spicy food and a burning sensation in the underlying mucosa. Upon inspection adhesion of the lower lip to the mandibular anterior vestibule, with a whitish appearance of the underlying mucosa was found. Treatment plan included vestibular deepening followed by non-eugenol surgical dressing and periodontal pack (COE-PAK) for 1 week. After 1 week uneventful healing was noted and the vestibule was no longer attached to the lower lip. Follow-up periods of 1 week, 1 month and 3 months showed complete healing and no reoccurrences of adhesion. Ingestion of caustic material may result in tissue and organ damage leading to a wide range of complications, including loss of functions.¹ This is dependent on a variety of factors which include strength (pH) or concentration of the material, the quantity ingested, the manner and duration of

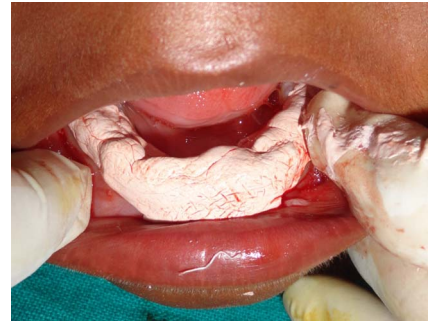


Figure 3 With COE-PAK dressing.

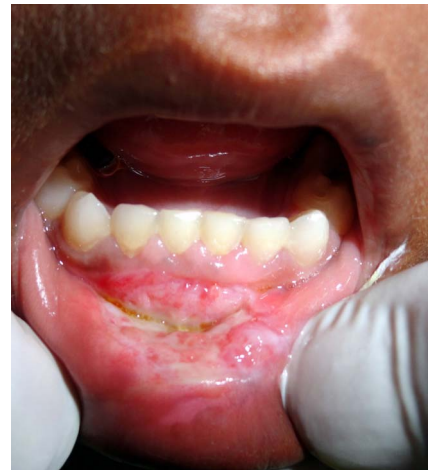

Figure 4 After 1 week postoperative.

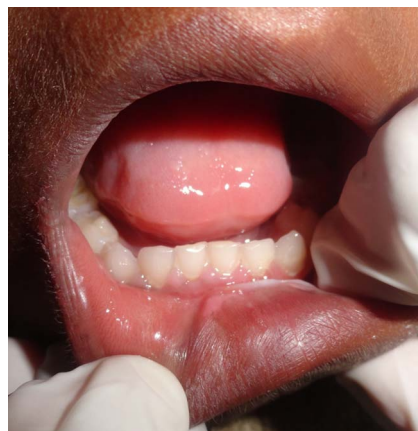

Figure 1 Preoperative.

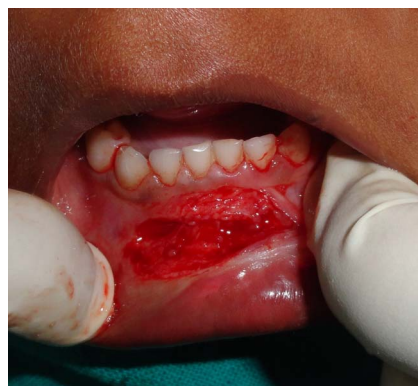

Figure 2 After incision.

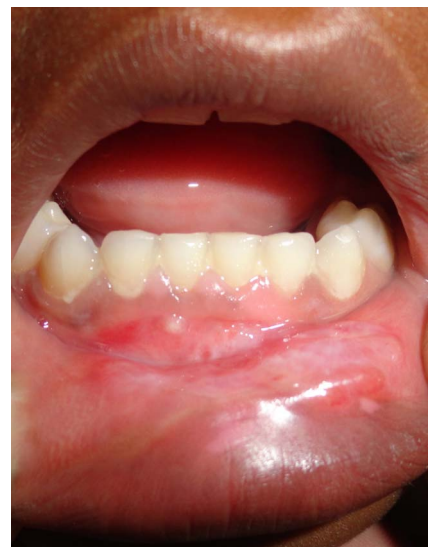

Figure 5 1 month postoperative.

To cite: Rallan M, Malhotra G, Rallan NS, et al. *BMJ Case Rep* Published online: [please include Day Month Year] doi:10.1136/bcr-2013-009083

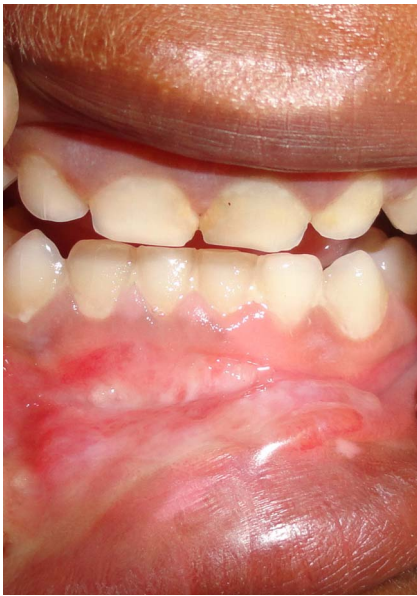

Figure 6 3 months postoperative.

particularly destructive because of their lytic action on tissues. Various treatment options may be offered to patients with caustic acid ingestion, like topical and intralesional corticosteroids, commissuroplasties, mucosal flaps, free radial

forearm flap and free-jejunal graft,¹ electrocautery and soft tissue laser. Taking into consideration the patient's age, cooperation, financial condition vestibular deepening followed by COE-PAK was opted which shows good results with no recurrences (figures 1–6).

Learning points

After accidental ingestion of chemical:

- ▶ Give large quantities of water.
- ▶ Induce vomiting.
- ▶ In case of shortening of breadth give O₂ and seek medical attention.

Competing interests None.

Patient consent Obtained.

Provenance and peer review Not commissioned; externally peer reviewed.

REFERENCES

- 1 Kumar S, Rana AS, Gupta D, *et al.* Unusual presentation of caustic ingestion and its surgical treatment: A case report. *J Maxillofac Oral Surg* 2011;10:74–6.
- 2 Manjunath DM, Prakash PG, Madhav SS "Tetracycline hydrochloride burn" as self-inflicted mucogingival injury a rare case report. *J Ind Soc Periodont* 2012;16:282–5.

Copyright 2013 BMJ Publishing Group. All rights reserved. For permission to reuse any of this content visit <http://group.bmj.com/group/rights-licensing/permissions>.

BMJ Case Report Fellows may re-use this article for personal use and teaching without any further permission.

Become a Fellow of BMJ Case Reports today and you can:

- ▶ Submit as many cases as you like
- ▶ Enjoy fast sympathetic peer review and rapid publication of accepted articles
- ▶ Access all the published articles
- ▶ Re-use any of the published material for personal use and teaching without further permission

For information on Institutional Fellowships contact consortiasales@bmjgroup.com

Visit casereports.bmj.com for more articles like this and to become a Fellow