Large dermoid cyst of the left hip: radiological approach with histopathology assessment

Kostas K P Psaras,[1] George Triantos,[2] Tsambikos Papavassiliou,[2] Alexandros Kotis[1]

[1]CT and MRI Department, General Hospital of Rhodes/GR, Rhodes, Dodecanese, Greece
[2]1st Surgery Department, General Hospital of Rhodes, Rhodes, Dodecanese, Greece

Correspondence to
Kostas K P Psaras, cospsa@gmail.com

DESCRIPTION

A 72-years-old woman presented to the emergency department for evaluation of a large soft tissue mass (figure 1). X-ray film and ultrasound soft tissue of the left hip were carried out. On X-ray a large soft tissue mass was discovered (figure 2). The patient was then followed with musculoskeletal ultrasound (Philips HD11 with head transducer L12-3) and revealed a lesion of mix type 7×7.5 cm with internal echogenicity and microcalcifications (figures 3 and 4), and later underwent MRI Philips intera. The protocol included imaging in transverse and coronal level, with sequences T2-weighted, short-tau inversion recovery and gradient echo with fat-suppression before and after intravenous injection of paramagnetic contrast, and discovered an enhancing signal mass with multiple scattered low signal microfoci that correspond in fibrous elements, keratin debris, microcalcifications and patchy peripheral uptake of the lesion (figures 5–8). When the patient was lead to the operating room for mass excision, the specimen was sent for biopsy and was assessed the diagnosis of a large dermoid cyst.

Dermoid cyst is a cystic teratoma that includes mature skin completely with hair follicles and sweat glands, sometimes hair, and often pockets of sebum, blood, fat, bone, nails, teeth, eyes, cartilage and thyroid tissue. Because it contains mature tissue, a dermoid cyst is almost always benign. The rare malignant dermoid cyst develops squamous cell carcinoma in adults; in babies and children it can develop into an endodermal sinus tumour.[1] Additionally, regarding the skin, dermoid cysts could be intracranial, intraspinal or perispinal. The term dermoid cyst can be found in all disciplines; however the common factor is the presence of a solitary or multiple hamartomatous tumour. The tumour is covered by a thick wall which contains sebaceous glands and all skin adnexa. In addition, hairs and large amounts of fatty masses originated from the ectoderm can be found. Dermoid cysts can be discovered as cutaneous cysts on the head, as cysts on the floor of the mouth or elsewhere in the head, within the parotid gland[2] or as cysts in the testes or penis. They can be large.[3] Depending on the location of the lesion, dermoid cysts may contain substances such as nails and dental, cartilage-like and bone-like structures. If limited to the skin or subcutaneous tissue, dermoid cysts are thin-walled tumours that could contain different amounts of fatty contents. Radiography, CT scanning and MRI are promising imaging methods in making the correct differential diagnosis of dermoid cysts. MRI is particularly helpful in diagnosing intracranial or intramedullary dermoid cysts

Figure 1 The mass in the outer posterior soft tissue surface of the left hip.

Figure 2 Conventional X-ray film of the left hip with visualised soft tissue density mass (arrows).

To cite: Psaras KKP, Triantos G, Papavassiliou T, *et al*. *BMJ Case Rep* Published online: [*please include* Day Month Year] doi:10.1136/bcr-2012-007943

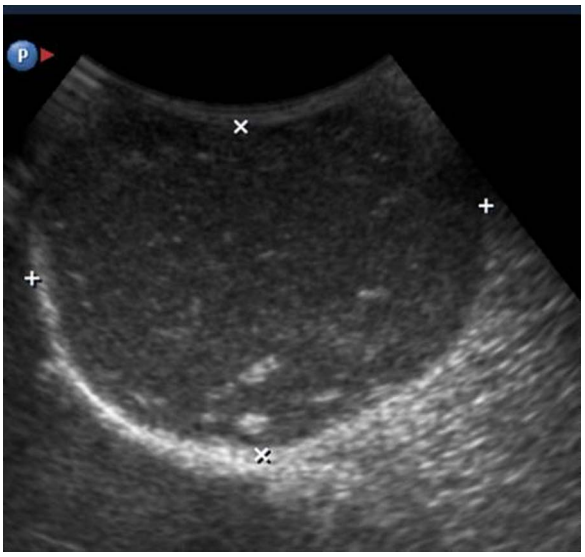

Figure 3 Ultrasound imaging showing a lesion of mixed type 7×7.5 cm with internal echogenicity and microcalcifications.

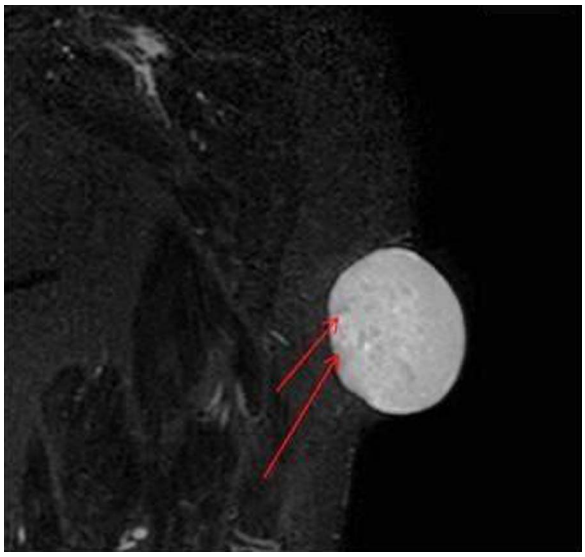

Figure 5 Coronal short-tau inversion recovery, TR 10371 TE80. High signal intensity mass with multiple internal low-intensity spots that correspond in fibrous elements, keratin and debris.

and in assessing the dissemination of fatty masses or droplets. In some patients, surgery should be performed more carefully because the fatty content of the cyst may spread to the surrounding tissues or anatomic structures, especially if the cyst is infected. The spread of these contents can create foreign body reactions and severe complications. If dermoid cysts are diagnosed early and treated with complete surgical excision, the prognosis is good, and no further complications are expected. In our case we followed the proper practice of imaging methods for surgery planning and for therapeutic success.

Figure 4 Ultrasound imaging showing internal echogenicity debris (arrow), prominent calcifications (curved arrow) and peripheral hypoechoic capsule mass blood supplied (open arrow).

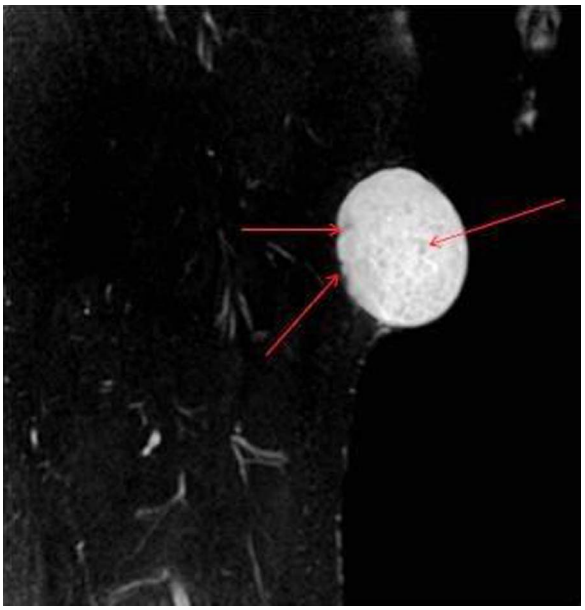

Figure 6 Coronal T2 fat sat, TR 7115 ms TE 100 ms. High signal intensity mass with multiple internal low-intensity spots (arrows) that correspond in fibrous elements, keratin and debris.

Figure 7 Coronal T1-weighted image, TR 650 ms TE 15 ms. Low signal intensity mass.

Figure 8 T1 coronal fat sat with GD. Peripheral patchy enhancement (arrows).

Learning point

Ultrasound and MRI offer the ability to the surgeon to perform the right surgery plan and assessing the best therapeutic success.

Acknowledgements The authors would like to thank their department and the staff of 1st Surgery Department for their help in completing this work.

Competing interests None.

Patient consent Obtained.

Provenance and peer review Not commissioned; externally peer reviewed.

REFERENCES

1 Freedberg IM, Goldsmith LA, Katz S, *et al*. eds. *Fitzpatrick's dermatology in general medicine*. 6th edn. New York: McGraw-Hill, 2003.
2 Tas A, Yagiz R, Altaner S, *et al*. Dermoid cyst of the parotid gland: first pediatric case. *Int J Pediatr Otorhinolaryngol* 2010;74:216–17.
3 Kahraman A, Kahveci R. A giant dermoid cyst. *Dermatol Surg* 2008;34:1273–5.