BMJ Case Reports

BMJ Case Reports: first published as 10.1136/bcr-2012-007142 on 9 November 2012. Downloaded from http://casereports.bmj.com/ on 19 April 2024 by guest. Protected by copyright.

Images in…

Tension pneumothorax accompanied by type A aortic dissection

Toru Hifumi, Nobuaki Kiriu, Junichi Inoue, Yuichi Koido

Department of Critical Care and Traumatology, National Disaster Medical Center, Tokyo, Japan

Correspondence to Dr Toru Hifumi, hifumitoru@gmail.com

Summary

A 51-year-old man was brought to the emergency room because of a sudden onset of severe dysponea. On presentation, his blood pressure was 94/55 mm Hg. Oxygen saturation was 86% while he was receiving 10 l/min oxygen through a non-rebreather mask. On physical examination, no jugular venous distention was noted, but breath sounds over the left lung were diminished. A bedside chest radiograph showed left tension pneumothorax, for which urgent needle decompression followed by chest thoracostomy was performed. Ventricular tachycardia developed, but a biphasic shock at 120 J immediately restored normal sinus rhythm. His vital signs, however, did not improve. A CT scan of the chest showed type A aortic dissection with bullae in the upper lobe of the left lung. He had an emergency operation for distal aortic arch displacement and was discharged on the 37th day of hospitalisation.

BACKGROUND

Both tension pneumothorax and type A aortic dissection have a high death rate and are challenging conditions for emergency physicians to stabilise. To our knowledge, this is the first report on tension pneumothorax with type A aortic dissection.

CASE PRESENTATION

A 51-year-old man was brought to our hospital for shortness of breath and dysponea. His wife called an ambulance when she found him lethargically lying in bed, early in the morning. He had been in his usual state of health until 1 week prior to admission, when he developed nausea, appetite loss and night sweats. He had complained of shoulder pain 2 days prior to admission. His past- medical history was significant for atrial fibrillation and retinal detachment. He smoked one pack of cigarettes per day. His family medical history was unremarkable.

On presentation, the patient was in respiratory distress. Vital signs were as follows: blood transfusion (BT), 32.5°C; blood pressure (BP), 94/55 mm Hg; HR, 179 beats/min; RR, 19 breaths/min. No jugular vein distension or tracheal deviation was seen and breath sounds over the left lung were diminished. The rest of the examination was unremarkable.

Complete blood cell counts (CBC) initially showed a white blood count of 13 600/µl; haematocrit, 39.7% and platelet count, 284 000/µl. Arterial blood gas analysis conducted while the patient was breathing 10 l/min of oxygen via non-rebreather mask showed pH 7.127; PCO_2, 33.6 mm Hg; PO_2, 71.5 mm Hg and oxygen saturation, 86%. An intravenous line was maintained and ECG was obtained immediately.

A chest x-ray showed tension pneumothorax (figure 1A). Therefore, needle thoracocentesis followed by tube thoracostomy was performed immediately, and the patient was nasotracheally intubated for airway protection (figure 1B). Ventricular tachycardia developed, but a biphasic shock at 120 J immediately restored normal sinus rhythm. His vital signs, however, did not improve. At that time, we required a better evaluation of the chest and therefore, we performed contrast-enhanced chest CT examination, which showed type A aortic dissection and bilateral bullae (figure 1C–E).

INVESTIGATIONS

Contrast-enhanced chest CT is the relevant investigation.

TREATMENT

He underwent total arch replacement under general anaesthesia.

OUTCOME AND FOLLOW-UP

His postoperative course was uneventful, and he was discharged on the 37th day.

He was seen in the cardiovascular surgery clinic for follow-up.

DISCUSSION

Marfan's syndrome was the suspected cause of tension pneumothorax and type A aortic dissection.[1 2] However, there was no family history of Marfan's syndrome or ectopia lentis, and skeletal findings were not confirmed. Ophthalmology consultation was performed during his stay in the hospital, and no significant abnormalities were seen.

Patient reports a pack-a-day smoking habit, and CT scan revealed left upper lobe bullae. According to the patient history, shoulder pain was present 2 days prior to admission. It is less likely for the patients with type A aortic dissection with patent false lumen to survive for several days without emergency operation. The information suggested that pneumothorax occurred earlier.

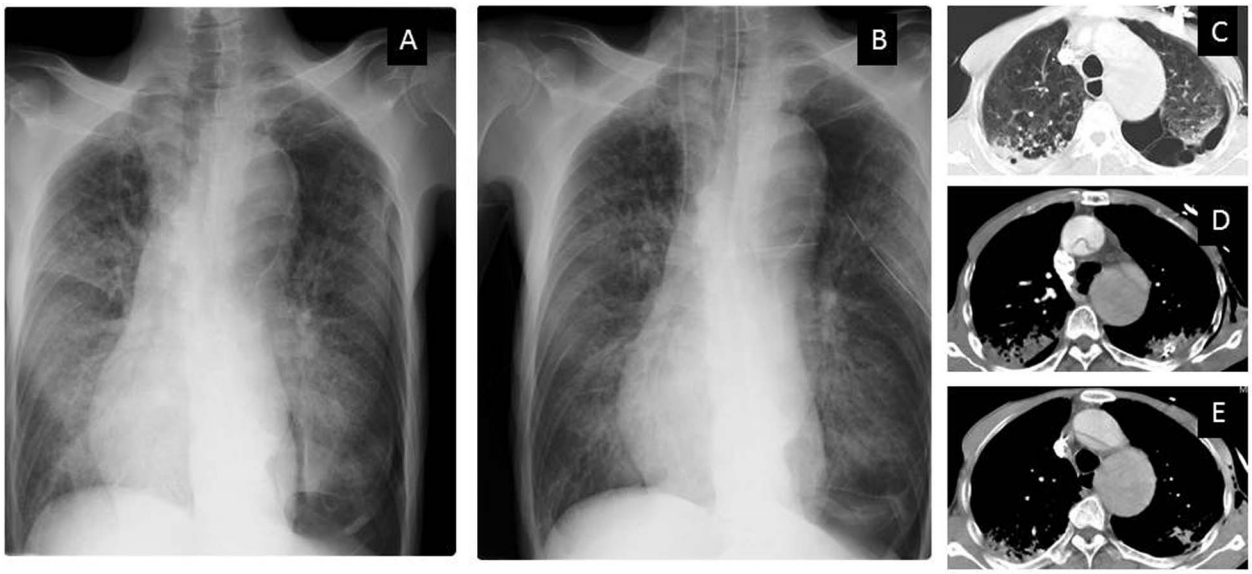

Figure 1 (A) An x-ray of the chest showing collapsed left hemithorax and mediastinal shift to the right. (B) An x-ray of the chest showing a chest tube inserted through the fifth left intercostal space. Central line was placed via the right jugular vein. Tracheal tube was placed, and left pneumothorax improved slightly. (C) A chest CT scan showing left upper lobe bullae and left pneumothorax. (D and E) Contrast-enhanced CT images revealed type A aortic dissection.

We concluded that this patient developed type A aortic dissection following spontaneous pneumothorax with ruptured bullae, because progressive pneumothorax increased intrathoracic pressures to such extent as to cause type A aortic dissection in a patient with an aortic aneurysm.

Learning points

- Both type A aortic dissection and tension pneumothorax can occur simultaneously.
- It is important to confirm the diagnosis of tension pneumothorax prior to obtaining the chest x-ray.
- Patients with tension pneumothorax whose condition does not improve after tube thoracostomy must be carefully re-evaluated.

Competing interests None.

Patient consent Obtained.

REFERENCES

1. **Sakata K.** Two cases of Marfan syndrome, surgically treated for complicating spontaneous pneumothorax. *Nippon Kyobu Geka Gakkai Zasshi* 1992;**40**:286–9.
2. **Wells DG,** Podolakin W. Anaesthesia and Marfan's syndrome: case report. *Can J Anaesth* 1987;**34**:311–14.

Copyright 2012 BMJ Publishing Group. All rights reserved. For permission to reuse any of this content visit http://group.bmj.com/group/rights-licensing/permissions.
BMJ Case Report Fellows may re-use this article for personal use and teaching without any further permission.

Please cite this article as follows (you will need to access the article online to obtain the date of publication).

Hifumi T, Kiriu N, Inoue J, Koido Y. Tension pneumothorax accompanied by type A aortic dissection. *BMJ Case Reports* 2012;10.1136/bcr-2012-007142, Published XXX

Become a Fellow of BMJ Case Reports today and you can:
- Submit as many cases as you like
- Enjoy fast sympathetic peer review and rapid publication of accepted articles
- Access all the published articles
- Re-use any of the published material for personal use and teaching without further permission

For information on Institutional Fellowships contact consortiasales@bmjgroup.com

Visit casereports.bmj.com for more articles like this and to become a Fellow

BMJ Case Reports: first published as 10.1136/bcr-2012-007142 on 9 November 2012. Downloaded from http://casereports.bmj.com/ on 19 April 2024 by guest. Protected by copyright.