BMJ Case Reports

Images in...

Bowel injury after a routine change of suprapubic catheter

Antoine Kass-Iliyya, Kate Morgan, Rupert Beck, John Iacovou

Department of Urology, Great Western Hospital, Swindon, UK

Correspondence to Antoine Kass-Iliyya, antoinekass@hotmail.co.uk

DESCRIPTION

An 81-year-old woman who had a long-term silicone suprapubic catheter (SPC) presented to hospital—few hours following a routine change of the catheter in the community—reporting drainage of a faeculent matter. The patient was clinically well. A suspicion of a colo-vesical fistula was raised and a CT scan of the abdomen and pelvis was carried out. The latter showed that the SPC was situated entirely outside the bladder with the tip of the catheter located inside the descending colon (figures 1 and 2). Studying the CT scan images it became apparent that the catheter had not entered the bladder's cavity but rather it had eroded its way around the bladder and perforated the descending colon.

The fact that the patient had no symptoms weighed heavily into our decision to manage the patient conservatively. A urethral catheter was inserted and the SPC was left in situ for 2 weeks. Subsequently, the SPC was removed and the patient remained well. Four weeks later she underwent a repeat CT scan. This did not show any obvious malignancy or fistula; however, it showed that the sigmoid colon is in close proximity to the antero-lateral wall of the bladder (figures 3 and 4).

Searching the literature we identified two similar case reports,[1 2] in which we agree with the authors' conclusion that viscus perforation is more likely to occur when the catheter material is not soft as demonstrated in this case, also patients with chronic inflammatory conditions such as UTIs, or diverticulitis are at higher risk of viscus injury.

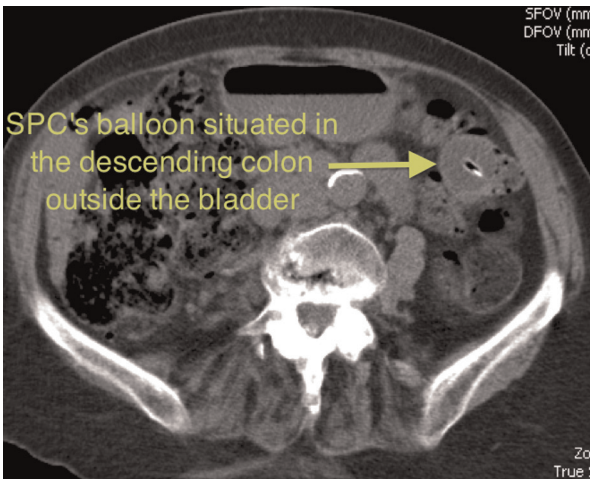

Figure 1 CT scan of the lower abdomen and pelvis showing the suprapubic catheter's baloon situated in the descending colon outside the bladder.

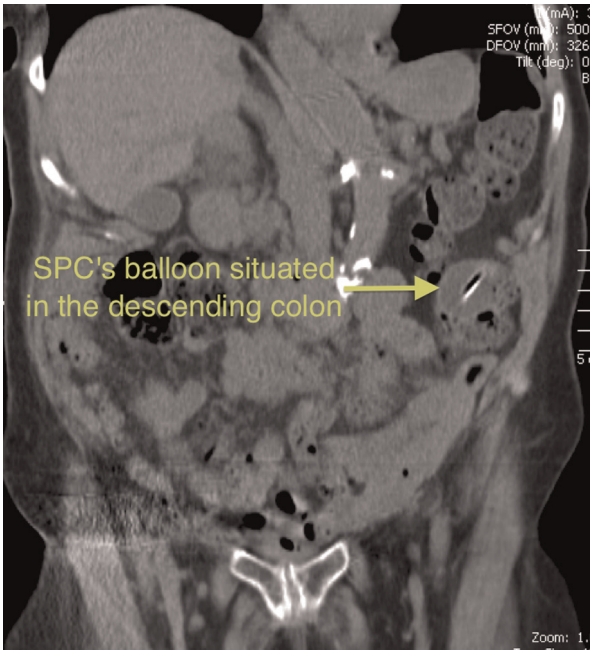

Figure 2 CT scan of the abdomen and pelvis on admission showing the suprapubic catheter situated in the descending colon.

Learning points

- Bowel injury is a recognised complication of suprapubic catheter (SPC) insertion, this could happen at the time of first insertion or during a routine change of the catheter. Risk factors for viscus injury are rigid catheters and chronic inflammatory conditions.
- Bowel injury could be occult and the patient remains asymptomatic despite a significant injury.
- There is a place for a conservative management of bowel injury secondary to SPC insertion depending on the individual patient.

Competing interests None.

Patient consent Obtained.

Figure 3 CT scan of the abdomen and pelvis 4 weeks after removal of the suprapubic catheter with no obvious signs of malignancy or fistula.

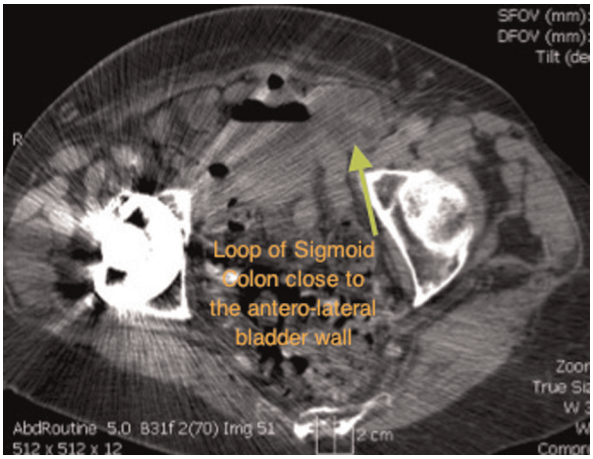

Figure 4 CT scan of the pelvis showing a sigmoid loop neighbouring the antero-lateral wall of the bladder.

REFERENCES

1. **Pieretti RV,** Pieretti-Vanmarcke RV. Late intraperitoneal posterior bladder wall perforation caused by loose percutaneous Stamey suprapubic catheter. *Pediatr Surg Int* 1995;**10/8**:0179–358.
2. **Witham M,** Martindae A. Occult transfixation of the sigmoid colon by suprapubic catheter. *Age Ageing* 2002;**31**:407–8.