BMJ Case Reports

Images in...

A case of a large ovarian tumour

Alexandros Kotis,[1] Stylianos Karatapanis,[2] Vasilios Papamargaritis,[3] Philipos Lisgos,[2] George Sisamotos[3]

[1]CT and MRI Department, General Hospital of Rhodes, Rhodes, Greece;
[2]1st Department of Internal Medicine, General Hospital of Rhodes, Rhodes, Greece;
[3]Ob/Gyn Department, General Hospital of Rhodes, Rhodes, Greece

Correspondence to Alexandros Kotis, kotisnet@otenet.gr

DESCRIPTION

An 18-year-old female presented to the emergency room complaining of atypical pain in the right hypocondrium. Clinical examination revealed the presence of an extensive mass in the right abdomen. Transvaginal ultrasonography (TVUS) detected the presence of a large anechoic, multilocular lesion (16×12×15 cm, with more than five locules), with septums <3 mm and colour score 1 (based on International Ovarian Tumor Analysis publication), which originated from the right ovary. The ultrasound findings were confirmed on CT scan (figure 1). At gynaecological laparotomy, a complex lesion consisting of multilocular elements and the falloppian tube was found. The latter was totally excised. Macroscopically, we observed a mass, which comprised the ovarian lesion and the tube, and which was characterised by lobularity (figures 2 and 3). Drainage revealed serous fluid. Histopathology showed characteristics of serous cystadenoma.

Ovarian cysts are found in transvaginal sonograms in nearly all premenopausal women and in up to 18% of postmenopausal women.[1] Most of these cysts are functional in nature and benign. Ovarian cysts can be found in almost all prememopausal women and about 15% of postmenopausal women. The most common cysts are formed during the normal menstrual cycle and can be either follicular or luteal in origin. These cysts are benign and can range in size from 1 cm to 8 cm. Haemorrhage inside the cyst results in the so-called chocolate cyst. When an adnexal mass is suspected, TVUS is the imaging modality of choice. TVUS and serial measurements of the biomarker CA-125, have been included for the high-risk population.[2] Ultrasound findings can help to distinguish between benign and malignant tumours. Other than ultrasound, CT or MRI is useful for larger masses and for examining the abdomen for metastases.[3] Surgery is recommended for simple cysts larger than 5 cm and complex cysts of any size.

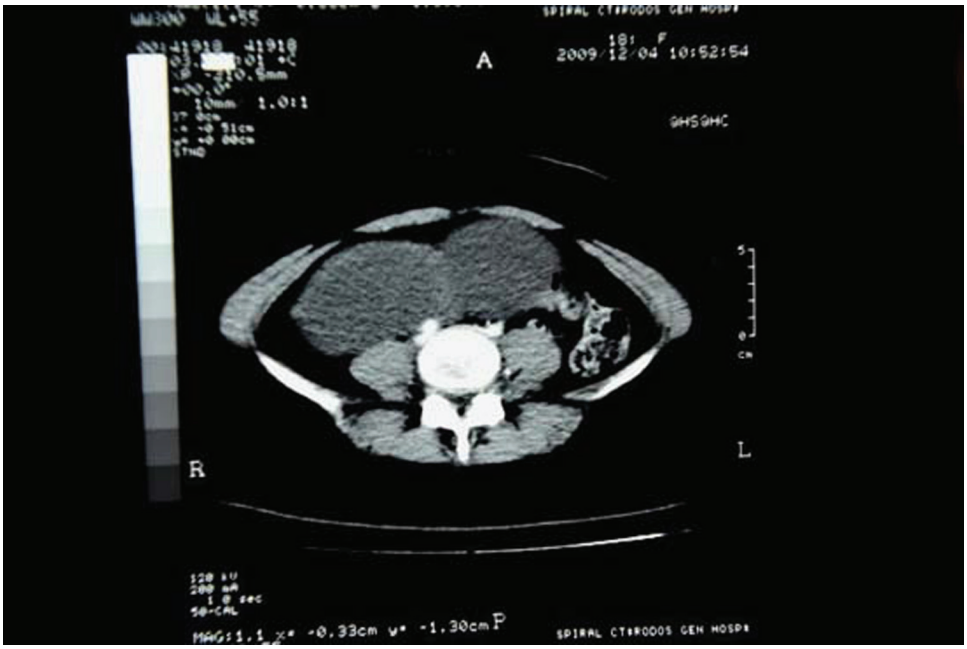

Figure 1 CT scan of a huge multiloculated adnexal mass.

BMJ Case Reports: first published as 10.1136/bcr.10.2010.3424 on 13 April 2011. Downloaded from http://casereports.bmj.com/ on 19 April 2024 by guest. Protected by copyright.

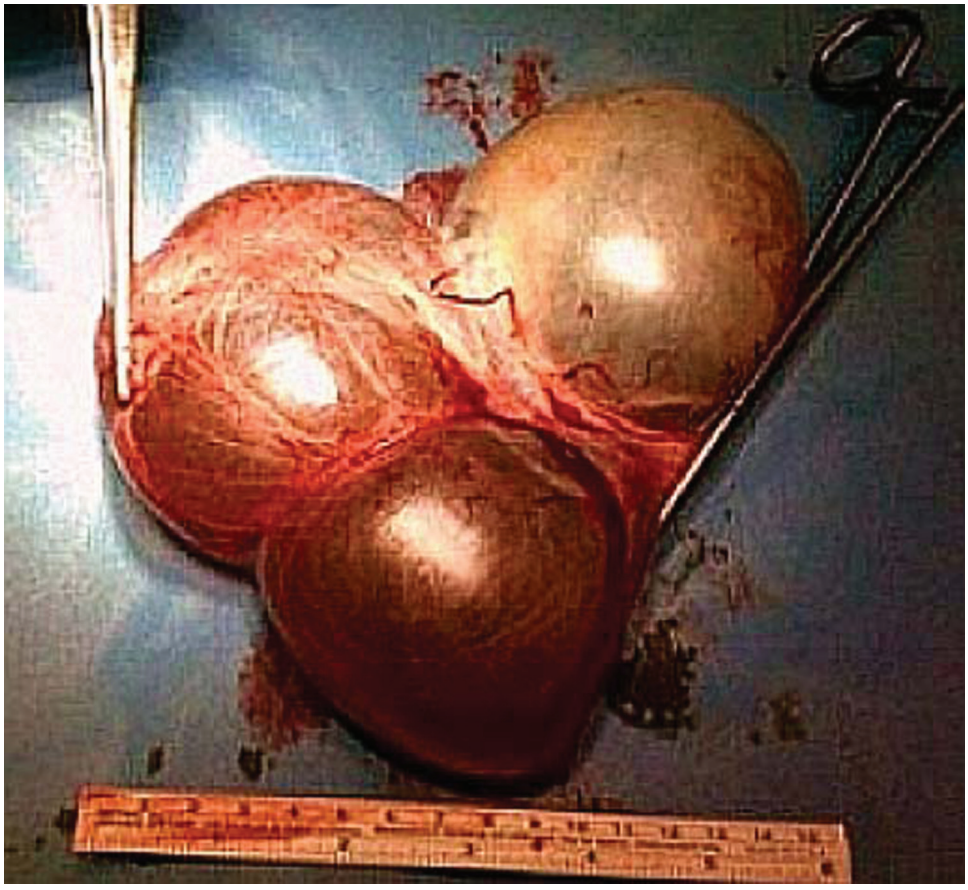

Figure 2 Macroscopic view of the specimen of the right ovary which seems to be a large multiloculated mass.

Figure 3 Similar view of the right ovarian mass.

BMJ Case Reports: first published as 10.1136/bcr.10.2010.3424 on 13 April 2011. Downloaded from http://casereports.bmj.com/ on 19 April 2024 by guest. Protected by copyright.

Acknowledgements The authors thank the First Internal Medicine Department and the Ob/Gyn Department, Dr Karatapanis and Dr Sisamotos for this exellent work to be published.

Competing interests None.

Patient consent Obtained.

REFERENCES

1. **Clement PB**. Anatomy and histology of the ovary. In: Kurman RJ, ed. *Blaustein's Pathology of the Female Genital Tract*. Fifth edition. 2002:649–673.
2. **Visintin I,** Feng Z, Longton G, *et al*. Diagnostic markers for early detection of ovarian cancer. *Clin Cancer Res* 2008;**14**:1065–72.
3. **Loyer EM,** Whitman GJ, Fenstermacher MJ. Imaging of ovarian carcinoma. *Int J Gynecol Cancer* 1999;**9**:351–61.

This pdf has been created automatically from the final edited text and images.

Copyright 2011 BMJ Publishing Group. All rights reserved. For permission to reuse any of this content visit
http://group.bmj.com/group/rights-licensing/permissions.
BMJ Case Report Fellows may re-use this article for personal use and teaching without any further permission.

Please cite this article as follows (you will need to access the article online to obtain the date of publication).

Kotis A, Karatapanis S, Papamargaritis V, Lisgos P, Sisamotos G. A case of a large ovarian tumour. *BMJ Case Reports* 2011;10.1136/bcr.10.2010.3424, date of publication

Become a Fellow of BMJ Case Reports today and you can:
- ► Submit as many cases as you like
- ► Enjoy fast sympathetic peer review and rapid publication of accepted articles
- ► Access all the published articles
- ► Re-use any of the published material for personal use and teaching without further permission

For information on Institutional Fellowships contact consortiasales@bmjgroup.com

Visit casereports.bmj.com for more articles like this and to become a Fellow

BMJ Case Reports: first published as 10.1136/bcr.10.2010.3424 on 13 April 2011. Downloaded from http://casereports.bmj.com/ on 19 April 2024 by guest. Protected by copyright.