BMJ Case Reports

BMJ Case Reports: first published as 10.1136/bcr.07.2010.3193 on 13 January 2011. Downloaded from http://casereports.bmj.com/ on 22 April 2024 by guest. Protected by copyright.

Unusual presentation of more common disease/injury

Unmasking the truth

D Cullington,[1] S Esmail,[1] S Hurren,[1] J G F Cleland,[2] A L Clark,[2] M F Alamgir[1]

[1]Cardiology Department, Hull and East Yorkshire Hospitals NHS Trust, Castle Hill Hospital, Kingston-Upon-Hull, UK;
[2]Academic Cardiology, University of Hull, Castle Hill Hospital, Kingston-Upon-Hull, UK

Correspondence to D Cullington, damiencullington@hotmail.com

Summary

In the emergency setting, shortness of breath is a frequent presenting complaint to physicians worldwide. The differential diagnosis is often broad and requires careful analysis of investigations to reach the correct diagnosis. The authors present a case of acute heart failure with a number of unusual presenting features that suggested an uncommon aetiology.

BACKGROUND

Acute heart failure is a common problem facing doctors in acute medical care. Usually occurring in patients with pre-existing heart failure, valvular disease or who present with acute coronary syndromes or tachyarrhythmias.[1] Over the last four decades, the management of the acutely breathless patient with heart failure has altered little. The standard use of oxygen, loop diuretics, opiates and nitrates relieves symptoms for most within a few hours. Familiarity can sometimes lead to complacency and some patients do not respond well to conventional treatment. We present a rare case of acute heart failure, which was refractory to standard treatment requiring urgent echocardiography to appropriately diagnose and tailor management.

CASE PRESENTATION

A 50-year-old man presented to our hospital's emergency department with a 3-day history of worsening dyspnoea. He denied experiencing angina, palpitations or syncope. He had no significant co-morbidities. Three months earlier he had ruptured his left Achilles tendon while playing football. This was treated with 10 weeks of below knee immobilisation and had been removed 3 weeks earlier. Preceding admission he had been otherwise well with no exertional limitation and was a keen medium-distance runner. There was no family history of inherited cardiac disease.

On clinical examination he was sweaty, tachypnoeic and hypoxic, his pulse was regular and measured 52/min and blood pressure was 106/60. His respiratory rate was 30/min. Auscultation of the chest revealed bilateral wheeze and basal crepitations. Heart sounds were normal and an ejection systolic murmur of varying intensity was audible and heard loudest at the left sternal edge and apex.

INVESTIGATIONS

Arterial blood gases on 15 litres/min of supplemental oxygen showed type I respiratory failure with a compensated metabolic acidosis (PaO_2=9.3 kPa, $PaCO_2$=4.0 kPa, bicarbonate=21.1 mmol/l, Base excess −4.8 mmol/l and pH=7.4).

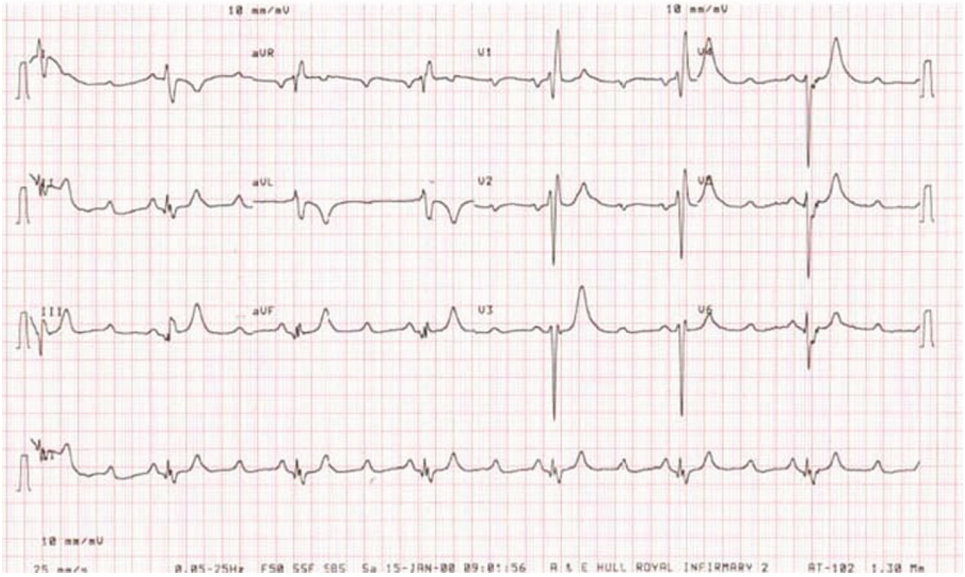

Figure 1 12 Lead electrocardiograph at acute presentation showing 3:1 second degree atrioventricular block.

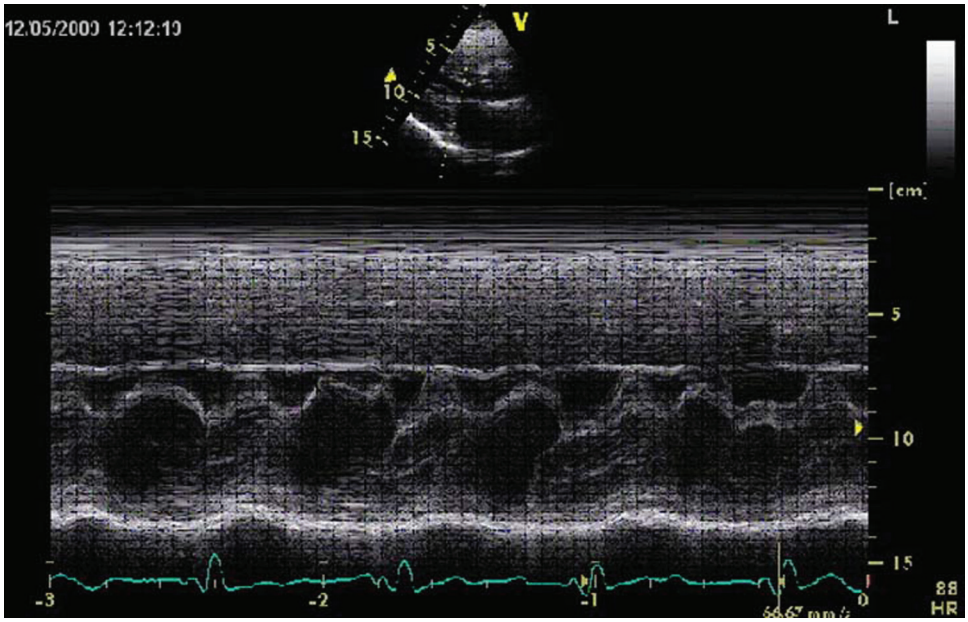

Figure 2 M-mode Doppler showing classical systolic anterior motion of the mitral valve prior to right ventricular pacing.

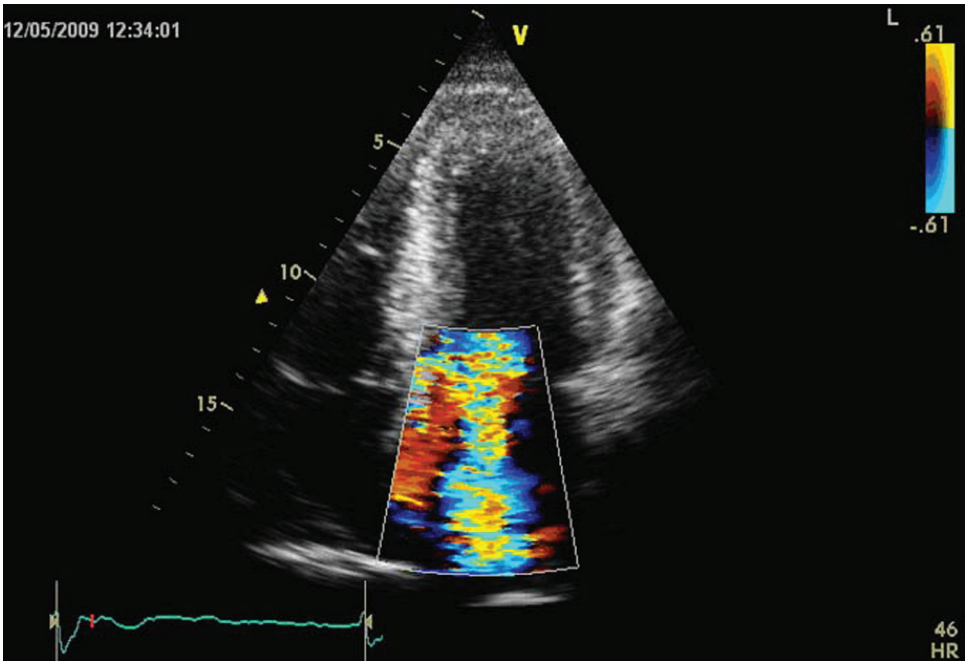

Figure 3 Colour Doppler showing severe class interventricular mitral regurgitation.

Initial ECG showed a heart rate of 42 bpm with right bundle branch block morphology and 3:1 second degree atrioventricular (AV) block, which intermittently reverted to a sinus bradycardia (figure 1).

Chest x-ray confirmed the presence of pulmonary oedema.

Urgent trans-thoracic echocardiogram performed during AV block showed good left ventricular (LV) contractility, hypertrophy of the anterior and septal LV walls (1.6 cm at end diastole), systolic anterior motion (SAM) of the mitral valve (figure 2), class IV mitral regurgitation (figure 3) and a dynamic LV outflow tract (LVOT) gradient with the peak velocity measuring 5.15 m/s (Peak gradient =106 mm Hg) (figure 4) There was no right ventricular (RV) dilation or measurable tricuspid regurgitation. No vegetations were seen.

CT pulmonary angiogram showed no thrombus within the pulmonary vasculature.

Troponin T level was elevated at 0.21 mcg/l.

DIFFERENTIAL DIAGNOSIS

The differential diagnosis is broad but, given the combination of pulmonary congestion coupled with ECG changes, it would suggest this is primarily a cardiac cause. The differentials were acute heart failure secondary to LV systolic impairment or valvular disease (de novo or acute on

BMJ Case Reports 2010; doi:10.1136/bcr.07.2010.3193

BMJ Case Reports: first published as 10.1136/bcr.07.2010.3193 on 13 January 2011. Downloaded from http://casereports.bmj.com/ on 22 April 2024 by guest. Protected by copyright.

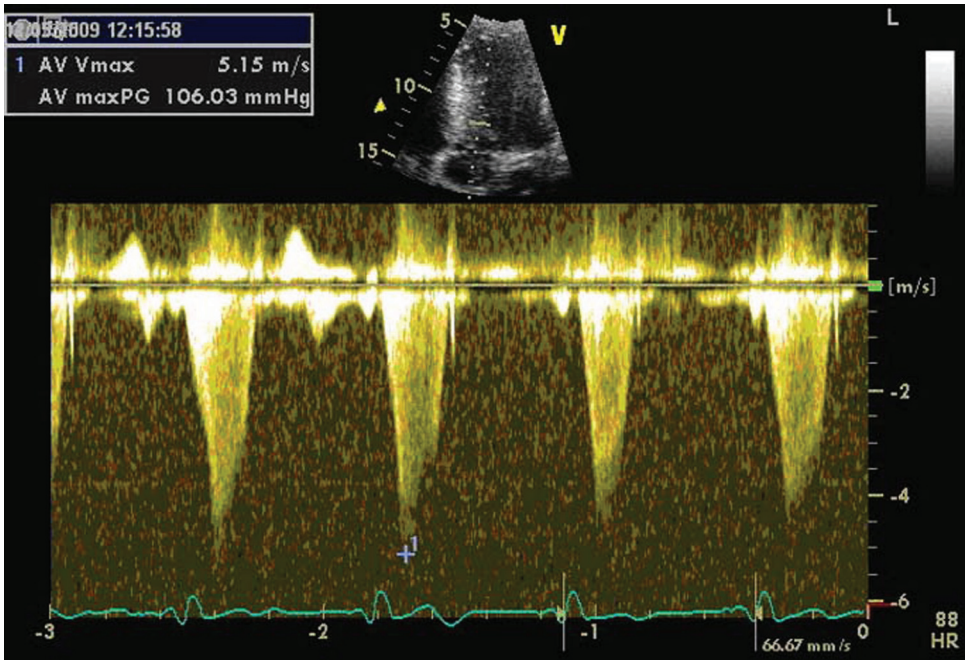

Figure 4 Continuous wave Doppler through the left ventricular outflow tract showing a severe gradient with classical dagger shaped contour.

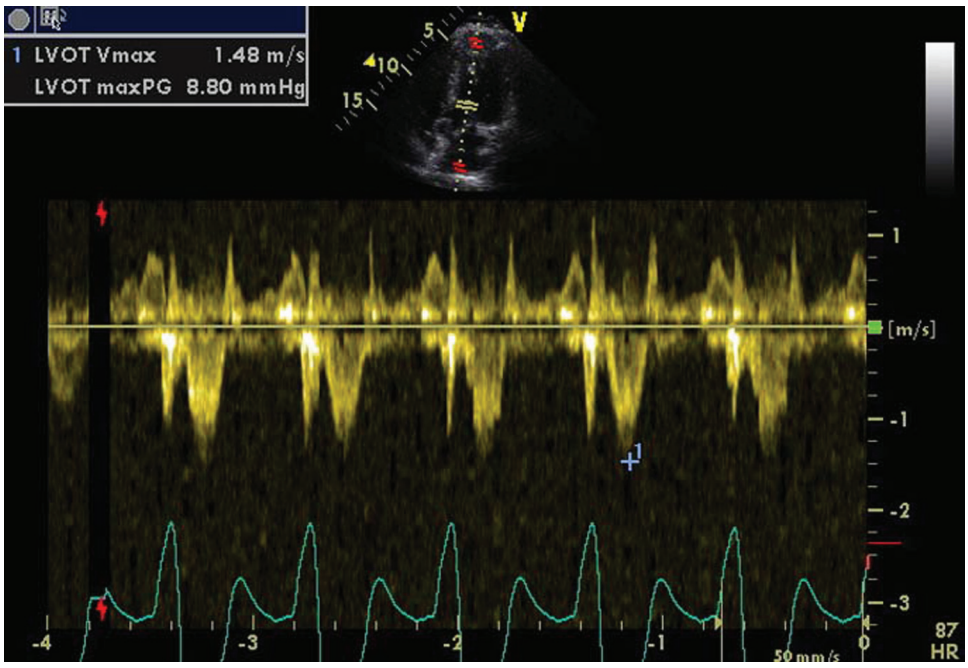

Figure 5 Six weeks after implantation of permanent pacing system, the resting left ventricular outflow tract gradient has decreased to 8.8 mm Hg.

chronic), bacterial endocarditis, sepsis, vasculitis or pulmonary embolism.

TREATMENT

Standard treatment consisting of intravenous morphine and diuretics was given initially but the underlying aetiology of his presentation remained unclear. After transfer to the coronary care unit, it was observed that episodes of pulmonary oedema with marked dyspnoea coincided with a change in cardiac rhythm from sinus to second degree AV block. A temporary pacing wire was inserted and he was paced from the RV apex. Over the next 24 h there was marked clinical improvement. Temporary pacing significantly reduced the severity of mitral regurgitation, SAM and outflow tract obstruction. Coronary angiography showed normal coronary arteries. On day 3 of his admission, a dual-chamber rate adaptive pacemaker was implanted with a short programmed AV delay and he was started on β blockers.

BMJ Case Reports: first published as 10.1136/bcr.07.2010.3193 on 13 January 2011. Downloaded from http://casereports.bmj.com/ on 22 April 2024 by guest. Protected by copyright.

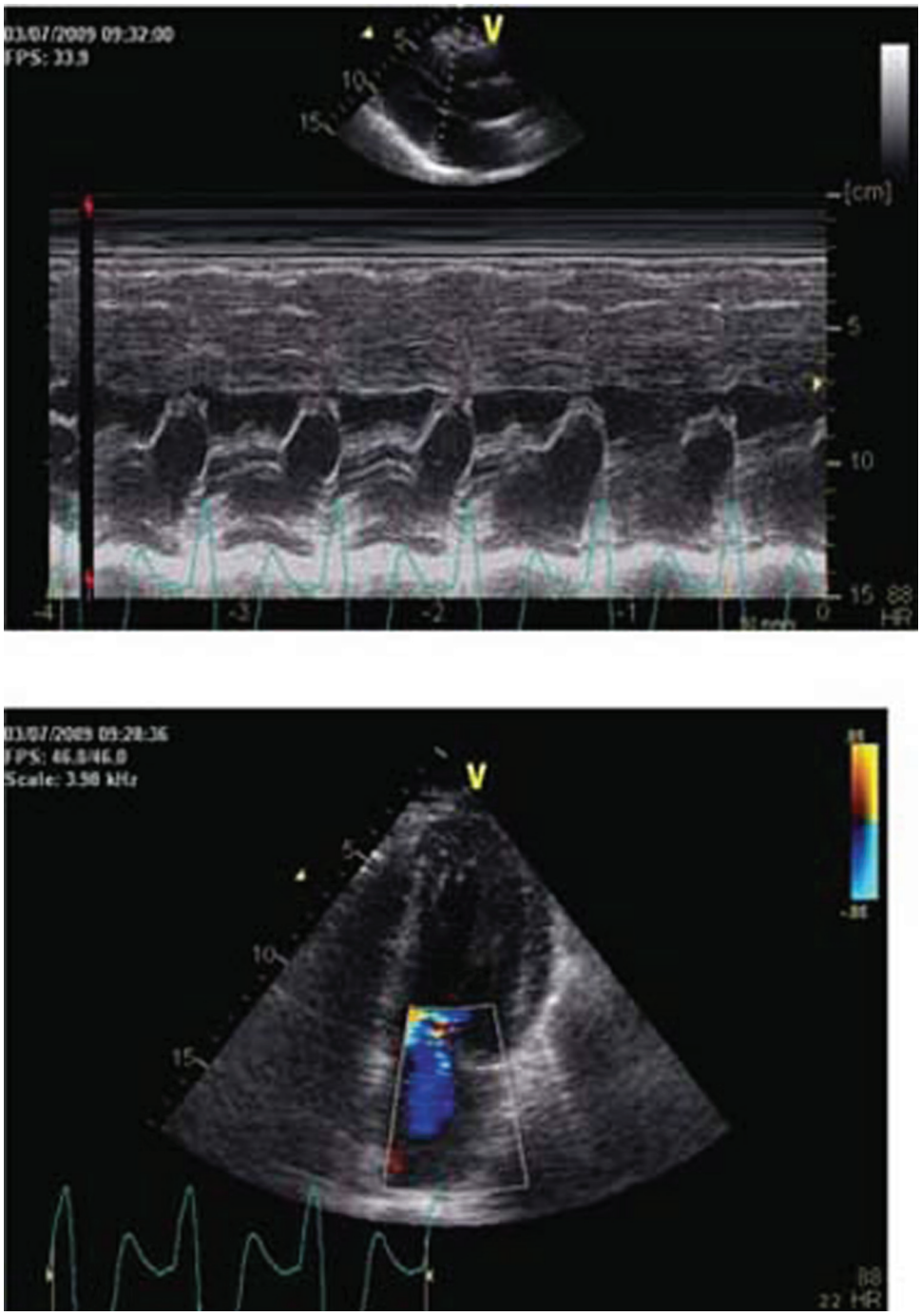

Figure 6 (A,B) After dual-chamber pacing with a short atrioventricular delay, M-mode Doppler shows complete resolution of systolic anterior motion of the mitral valve and colour Doppler shows only mild mitral regurgitation.

OUTCOME AND FOLLOW-UP

By 6–weeks' follow-up, he had complete resolution of symptoms and returned to his normal level of activity.

To rule out Fabry's disease we tested the level of α galactosidase and this was within the normal range. During maximal cardiorespiratory exercise testing using modified Bruce protocol he exercised for 14 min 37 s. His heart rate response was blunted but blood pressure response normal. The peak VO_2 was lower than predicted (21 ml/kg/min, respiratory exchange ratio at peak exercise=1.08) and Ve/VCO_2 slope elevated at 33 ml/kg/ min. Recumbent bicycle ergometry was performed using a ramp protocol. His resting LVOT peak velocity was now 1.9 m/s (14.4 mm Hg) (figure 5). He attained stage IV of the protocol. There was a marginal increase in the LVOT velocity to 2.2 m/s at maximal exertion. Only trivial mitral regurgitation was seen at rest and at peak exertion and no SAM (figures 6A,B).

DISCUSSION

Acute heart failure caused by hypertrophic cardiomyopathy (HCM) is rare. Angina, palpitations, exertional dyspnoea, dizzy spells or syncope are common presenting symptoms of HCM.[2] Our patient presented with the commonest clinically recognised phenotype of HCM affecting the

BMJ Case Reports: first published as 10.1136/bcr.07.2010.3193 on 13 January 2011. Downloaded from http://casereports.bmj.com/ on 22 April 2024 by guest. Protected by copyright.

anteroseptal region of the left ventricle.[3] Acute 'unmasking' of HCM secondary to AV block is rare.[4] Alteration in the normal AV coupling by AV block can induce significant LVOT obstruction in patients with HCM.[5 6] HCM variants that have conducting system disease or accessory pathways as part of their phenotypic expression are recognised.[7] His–Purkinje conduction abnormalities occur in approximately one-third of patients with HCM.[8]

Standard baseline medical treatment for HCM with LVOT obstruction includes β blockers, calcium channel antagonists and disopyramide.[9] Patients with refractory symptoms may be considered for dual-chamber pacing with a short AV delay as a second-line option. Cardiac anatomy, age of patient and associated co-morbidities and local expertise will determine whether referral for surgical myectomy or alcohol septal ablation is more appropriate than a pacing strategy.[10] Non-randomised studies in the 1990s suggested that dual-chamber pacing reduced the severity of LVOT obstruction and improved symptoms, but randomised controlled trials showed an equivocal correlation between the effects of pacing on the LVOT gradient and improvement in symptoms, quality of life and exertional capacity.[9 11–13] The randomised trials have a number of limitations and longer term data have shown that dual-chamber pacing improves quality of life.[14–16] In patients with refractory symptoms, surgical myectomy is superior to dual-chamber pacing in terms of reducing outflow tract gradient, improving symptoms and increasing exertional capacity.[17]

Dual-chamber pacing induces dyssynchronous interventricular contraction, altering the relationships between mitral valve structures and the interventricular septum during systole; thus, reducing LVOT obstruction.[10] Pacing also reduces the severity of mitral regurgitation.[18] In our patient, temporary RV apical pacing markedly reduced the LVOT gradient and severity of mitral regurgitation, which was primarily caused by acute AV block. Permanent dual-chamber pacing with short AV delay markedly reduced the LVOT gradient at rest and during exercise plus the severity of mitral regurgitation.

Heart failure is a complex medical condition with a poor prognosis when the problem cannot be found and corrected. A low threshold for cardiology referral and investigation may identify unusual causes of acute heart failure and improve outcomes.

Learning points

- Always evaluate patients with acute dyspnoea with an open mind.
- Patients presenting with acute heart failure should have echocardiography performed early in their management.
- Refer early for cardiology input if the initial response to medical management of heart failure is poor. Patients usually respond favourably within a few hours of standard treatment.

Competing interests None.

Patient consent Obtained.

REFERENCES

1. **Pang PS,** Komajda M, Gheorghiade M. The current and future management of acute heart failure syndromes. *Eur Heart J* 2010;**31**:784–93.
2. **Elliott P,** McKenna WJ. Hypertrophic cardiomyopathy. *Lancet* 2004;**363**:1881–91.
3. **Wigle ED,** Rakowski H, Kimball BP, *et al*. Hypertrophic cardiomyopathy. Clinical spectrum and treatment. *Circulation* 1995;**92**:1680–92.
4. **Yesil M,** Bayata S, Susam I, *et al*. Rare association of hypertrophic cardiomyopathy and complete atrioventricular block with prompt disappearance of outflow gradient after DDD pacing. *Europace* 1999;**1**:280–2.
5. **Johnson AD,** Daily PO. Hypertrophic subaortic stenosis complicated by high degree heart block: successful treatment with an atrial synchronous ventricular pacemaker. *Chest* 1975;**67**:491–4.
6. **Gilgenkrantz JM,** Cherrier F, Petitier H, *et al*. Obstructive cardiomyopathy of the left ventricle with complete auriculo-ventricular block: therapeutic considerations (in French). *Arch Mal Coeur Vaiss* 1968;**61**:439–53.
7. **Savage DD,** Seides SF, Clark CE, *et al*. Electrocardiographic findings in patients with obstructive and nonobstructive hypertrophic cardiomyopathy. *Circulation* 1978;**58**(3 Pt 1):402–8.
8. **Fananapazir L,** Tracy CM, Leon MB, *et al*. Electrophysiologic abnormalities in patients with hypertrophic cardiomyopathy. A consecutive analysis in 155 patients. *Circulation* 1989;**80**:1259–68.
9. **Maron BJ,** McKenna WJ, Danielson GK, *et al*. American College of Cardiology/European Society of Cardiology Clinical Expert Consensus Document on Hypertropic Cardiomyopathy. a report of the American College of Cardiology Foundation Task Force on Clinical Expert Consensus Documents and the European Society of Cardiology Committee for Practice Guidelines. *J Am Coll Cardiol* 2003;**42**:1687–713.
10. **Fifer MA,** Vlahakes GJ. Management of symptoms in hypertrophic cardiomyopathy. *Circulation* 2008;**117**:429–39.
11. **Fananapazir L,** Cannon RO3rdTripodi D, *et al*. Impact of dual-chamber permanent pacing in patients with obstructive hypertrophic cardiomyopathy with symptoms refractory to verapamil and beta-adrenergic blocker therapy. *Circulation* 1992;**85**:2149–61.
12. **Maron BJ,** Nishimura RA, McKenna WJ, *et al*. Assessment of permanent dual-chamber pacing as a treatment for drug-refractory symptomatic patients with obstructive hypertrophic cardiomyopathy. A randomized, double-blind, crossover study (M-PATHY). *Circulation* 1999;**99**:2927–33.
13. **Kappenberger L,** Linde C, Daubert C, *et al*. Pacing in hypertrophic obstructive cardiomyopathy. A randomized crossover study. PIC Study Group. *Eur Heart J* 1997;**18**:1249–56.
14. **Mohiddin SA,** Page SP. Long-term benefits of pacing in obstructive hypertrophic cardiomyopathy. *Heart* 2010;**96**:328–30.
15. **Galve E,** Sambola A, Saldaña G, *et al*. Late benefits of dual-chamber pacing in obstructive hypertrophic cardiomyopathy: a 10-year follow-up study. *Heart* 2010;**96**:352–6.
16. **Gadler F,** Linde C, Daubert C, *et al*. Significant improvement of quality of life following atrioventricular synchronous pacing in patients with hypertrophic obstructive cardiomyopathy. Data from 1 year of follow-up. PIC study group. Pacing In Cardiomyopathy. *Eur Heart J* 1999;**20**:1044–50.
17. **Ommen SR,** Nishimura RA, Squires RW, *et al*. Comparison of dual-chamber pacing versus septal myectomy for the treatment of patients with hypertrophic obstructive cardiomyopathy: a comparison of objective hemodynamic and exercise end points. *J Am Coll Cardiol* 1999;**34**:191–6.
18. **Pavin D,** de Place C, Le Breton H, *et al*. Effects of permanent dual-chamber pacing on mitral regurgitation in hypertrophic obstructive cardiomyopathy. *Eur Heart J* 1999;**20**:203–10.

BMJ Case Reports: first published as 10.1136/bcr.07.2010.3193 on 13 January 2011. Downloaded from http://casereports.bmj.com/ on 22 April 2024 by guest. Protected by copyright.

This pdf has been created automatically from the final edited text and images.

Copyright 2010 BMJ Publishing Group. All rights reserved. For permission to reuse any of this content visit
http://group.bmj.com/group/rights-licensing/permissions.
BMJ Case Report Fellows may re-use this article for personal use and teaching without any further permission.

Please cite this article as follows (you will need to access the article online to obtain the date of publication).

Cullington D, Esmail S, Hurren S, Cleland JGF, Clark AL, Alamgir MF. Unmasking the truth. *BMJ Case Reports* 2010;10.1136/bcr.07.2010.3193, date of publication

Become a Fellow of BMJ Case Reports today and you can:
- Submit as many cases as you like
- Enjoy fast sympathetic peer review and rapid publication of accepted articles
- Access all the published articles
- Re-use any of the published material for personal use and teaching without further permission

For information on Institutional Fellowships contact consortiasales@bmjgroup.com

Visit casereports.bmj.com for more articles like this and to become a Fellow

BMJ Case Reports: first published as 10.1136/bcr.07.2010.3193 on 13 January 2011. Downloaded from http://casereports.bmj.com/ on 22 April 2024 by guest. Protected by copyright.