BMJ Case Reports

Images in...

Posterior reversible encephalopathy manifested by refractory status epilepticus in two patients under chemotherapy

Henda Foreid,[1] Carolina Pires,[1] Luisa Albuquerque,[1] José Pimentel[1,2]

[1]Department of Neurosciences, Serviço de Neurologia, Hospital de Santa Maria, Lisbon, Portugal;
[2]Faculty of Medicine, University of Lisbon, Portugal

Correspondence to Dr Henda Foreid, henda.foreid@gmail.com

DESCRIPTION

Posterior reversible encephalopathy (PRES) is a clinical-radiological syndrome characterised by brain symmetric lesions of vasogenic oedema, in white matter, basal ganglia or cerebral cortex, preferentially in posterior topography.[1] Typical manifestations are headache and altered mental status. Epileptic seizures are also frequent, although status epilepticus (SE) is a rare occurrence.[2] Chemotherapy may trigger PRES. Nevertheless, no single chemotherapy agent was consistently implicated.[2]

Two cases are presented: a young man (patient 1) with a Hodgkin lymphoma, under ABVD chemotherapy (adriamicin, vinblastine, bleomicine, dacarbazin), and an adult woman (patient 2), under docetaxel and gemcitabine treatment due to a femoral sarcoma. Both patients were admitted with a non-convulsive SE. Brain resonance MRI depicted bilateral, predominantly parietal-occipital lesions, hyperintense on T2/ fluid attenuated inversion recovery and with no water restriction on diffusion-weighted MRI/apparent diffusion coefficient maps, consistent with vasogenic oedema (figure 1); patient 2 also presented intracranial vasospasm on magnetic resonance angiography. Both patients were successfully treated for the SE with antiepileptic drugs plus blood pressure control and nimodipine. The first patient repeated ABVD afterwards without recurrence of PRES. In the second patient, no further chemotherapy regimens were performed due to neoplasm refractoriness. Furthermore, both patients showed complete resolution of cytotoxic oedema on repeated MRI.

The association between PRES and platinum, taxanes, vinca alkaloids, biological agents and combination chemotherapy, is increasingly recognised. The exact mechanism of toxicity remains unknown. Vasospasm and loss of cerebrovascular auto-regulation, with the development of vasogenic oedema is a hypothesis. If PRES is left untreated, cytotoxic oedema and permanent neurological deficit may occur,[2] hence the need for an early recognition is required.

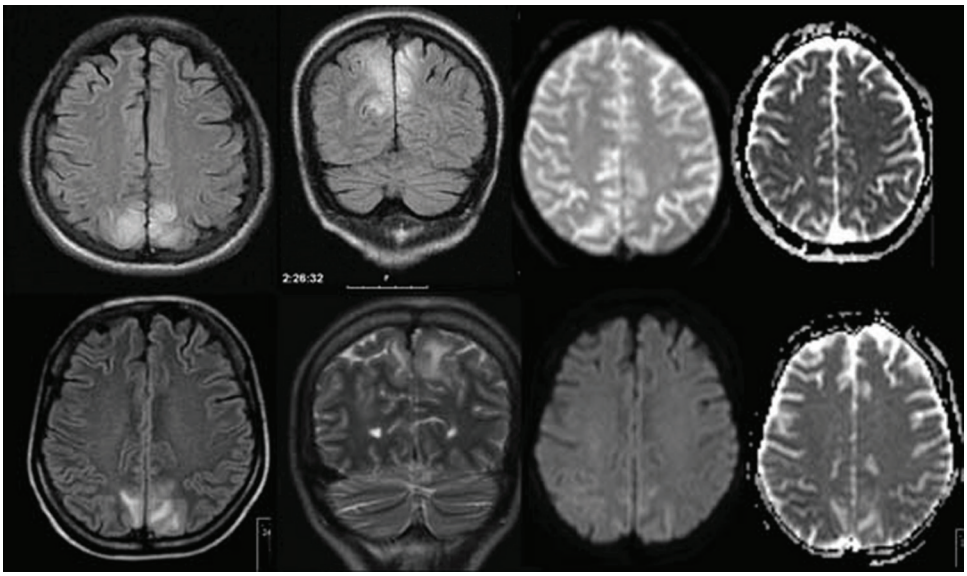

Figure 1 Brain MRI showing posterior hyperintense lesions on FLAIR/T2 sequences and no water restriction on DWI/ADC maps. Upper images form the first patient; bottom images from the second patient.

BMJ Case Reports: first published as 10.1136/bcr.05.2011.4181 on 5 August 2011. Downloaded from http://casereports.bmj.com/ on 24 April 2024 by guest. Protected by copyright.

Acknowledgements The authors acknowledge Dr Bruno Miranda, Dr Rita Peralta and Dr Carla Bentes.

Competing interests None.

Patient consent Not obtained.

REFERENCES

1. **Hinchey J,** Chaves C, Appignani B, *et al*. A reversible posterior leukoencephalopathy syndrome. *N Engl J Med* 1996;**334**:494–500.
2. **Bhatt A,** Farooq MU, Majid A, *et al*. Chemotherapy-related posterior reversible leukoencephalopathy syndrome. *Nat Clin Pract Neurol* 2009;**5**:163–9.

This pdf has been created automatically from the final edited text and images.

Copyright 2011 BMJ Publishing Group. All rights reserved. For permission to reuse any of this content visit
http://group.bmj.com/group/rights-licensing/permissions.
BMJ Case Report Fellows may re-use this article for personal use and teaching without any further permission.

Please cite this article as follows (you will need to access the article online to obtain the date of publication).

Foreid H, Pires C, Albuquerque L, Pimentel J. Posterior reversible encephalopathy manifested by refractory status epilepticus in two patients under chemotherapy. *BMJ Case Reports* 2011;10.1136/bcr.05.2011.4181, date of publication

Become a Fellow of BMJ Case Reports today and you can:
► Submit as many cases as you like
► Enjoy fast sympathetic peer review and rapid publication of accepted articles
► Access all the published articles
► Re-use any of the published material for personal use and teaching without further permission

For information on Institutional Fellowships contact consortiasales@bmjgroup.com

Visit casereports.bmj.com for more articles like this and to become a Fellow

BMJ Case Reports: first published as 10.1136/bcr.05.2011.4181 on 5 August 2011. Downloaded from http://casereports.bmj.com/ on 24 April 2024 by guest. Protected by copyright.