



OPEN ACCESS

Strongyloides stercoralis hyperinfection syndrome with cerebral involvement

Andreas Arnholdt Pedersen ^{1,2,3} Gitte Nyvang Hartmeyer ^{4,5}
Christen Rune Stensvold ⁶ Raquel Martin-Iguacel ¹

¹Department of Infectious Diseases, Odense University Hospital, Odense, Denmark

²Department of Pulmonary Research, Lillebaelt Hospital, Vejle, Denmark

³Department of Regional Health Research, University of Southern Denmark, Odense, Denmark

⁴Department of Clinical Microbiology, Odense University Hospital, Odense, Denmark

⁵Research Unit of Clinical Microbiology, University of Southern Denmark Faculty of Health Sciences, Odense, Syddanmark, Denmark

⁶Department of Bacteria, Parasites and Fungi, Infectious Disease Preparedness, Statens Serum Institut, Copenhagen, Denmark

Correspondence to

Dr Andreas Arnholdt Pedersen; Andreas.Arnholdt.Pedersen@rsyd.dk

Accepted 8 September 2022

SUMMARY

Strongyloidiasis is a disease caused by the intestinal helminth *Strongyloides stercoralis*. When the immune system of infected individuals is compromised, larvae may migrate from the gastrointestinal tract to other tissues, causing *S. stercoralis* hyperinfection syndrome, which has a reported mortality of 71%. In this case, we report a patient with *S. stercoralis* hyperinfection syndrome with central nervous system (CNS) involvement. An elderly South East Asian male tourist presented with pulmonary symptoms, fever and infiltrates on chest X-ray. He later developed symptoms of CNS infection. *S. stercoralis* larvae were found in a stool sample. Microbiological examination of cerebrospinal fluid revealed *S. stercoralis*-specific DNA. The patient was treated with oral and rectal ivermectin and albendazole. The condition was complicated by sepsis, bacteraemia and hypereosinophilia. Unfortunately, the patient eventually died from pulmonary oedema and insufficiency. This case highlights the global importance of *Strongyloides* CNS infection in endemic and non-endemic regions.

BACKGROUND

Strongyloidiasis is a common disease in the tropics and subtropics and is caused by the intestinal helminth *Strongyloides stercoralis*. This nematode is remarkable in its capacity to complete its lifecycle completely both inside and outside the host. In the host, the infection is usually initiated by filariform larvae penetrating intact skin. The larvae migrate through the alveoli to the respiratory tract and are swallowed and passed to the small intestine where they mature and deposit eggs in the intestinal mucosa. The eggs are then either excreted in the faeces or they hatch into rhabditiform larvae, changing into the infective filariform stage, which can reinfect the host by penetrating the bowel or the perianal skin. They can thus cause an autoinfection, which may last for several years, possibly decades.¹ The lifecycle of *S. stercoralis* is shown in figure 1.² Between 10% and 40% of the population in tropical and subtropical areas might be infected by *S. stercoralis*.³ In migrants from East Asia, the seroprevalence is 17.3%, and the prevalence based on detection of the larvae in stool is 3.9%.^{4,5} The estimated global prevalence of *S. stercoralis* is shown in figure 2.⁶ In immunocompromised individuals, the filariform larvae can disseminate to any organ, causing hyperinfection with a reported mortality of 71%.^{7,8} *S. stercoralis* hyperinfection syndrome may be seen in patients with human T-cell lymphotropic

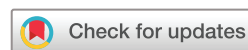virus type 1 or HIV/AIDS, patients suffering from malignant neoplasm, individuals with alcohol abuse, transplant patients and in patients treated with corticosteroids.^{1,9,10}

Here, we report a case of primary *S. stercoralis* central nervous system (CNS) infection, which is a rare manifestation of *S. stercoralis* hyperinfection syndrome.

CASE PRESENTATION

A South East Asian man in his 70s presented with cough and purulent sputum. His medical history included hypertension, myocardial infarction, nephrolithiasis and surgical stone extraction. He was a former smoker (30 pack-years) and reported no alcohol use. He was born and raised in South East Asia.

Six days after arrival, he complained of productive coughing, fever and was seen by a general practitioner and treated with phenoxymethylpenicillin for pneumonia (day 0). He was admitted to the emergency department on day 8 due to fever, malaise, nausea and headache. The physical examination revealed diffuse abdominal tenderness, normal chest auscultation and a few skin excoriations on his extremities. No other skin changes were noted. Again, he was treated for pneumonia based on the presence of bilateral infiltrates on chest X-ray (figure 3). Blood eosinophils were $2.46 \times 10^9/L$ on admission. He was discharged on day 9 after overall improvement. On day 15, he was readmitted due to new-onset seizures. Neurological examination was normal, and no skin changes were noted. CT scan of the head showed a small hypodense area in the corona radiata, interpreted as sequelae of cerebral infarction. The seizures were thus thought to be postinfarction seizures, and antiplatelet therapy was initiated. On day 52, he was readmitted to the emergency department with severe abdominal pain and fever. The blood eosinophil counts were $0.05 \times 10^9/L$ (figure 4). A distended and tender abdomen was found on physical examination. A CT scan of the abdomen revealed severe coprostasis and an oedematous caecum. He received empirical antibiotic treatment with piperacillin/tazobactam. The next day, his condition worsened with the development of a severe headache and nuchal rigidity. Lumbar puncture was performed, showing pleocytosis with $1300 \times 10^6/L$ cells (920×10^6 polymorphonuclear and 420×10^6 mononuclear cells), a glucose level of 3.6 mmol/L and a protein level of 3.55 g/L in the cerebrospinal fluid (CSF).



© BMJ Publishing Group Limited 2022. Re-use permitted under CC BY-NC. No commercial re-use. See rights and permissions. Published by BMJ.

To cite: Pedersen AA, Hartmeyer GN, Stensvold CR, et al. *BMJ Case Rep* 2022;**15**:e247032. doi:10.1136/bcr-2021-247032

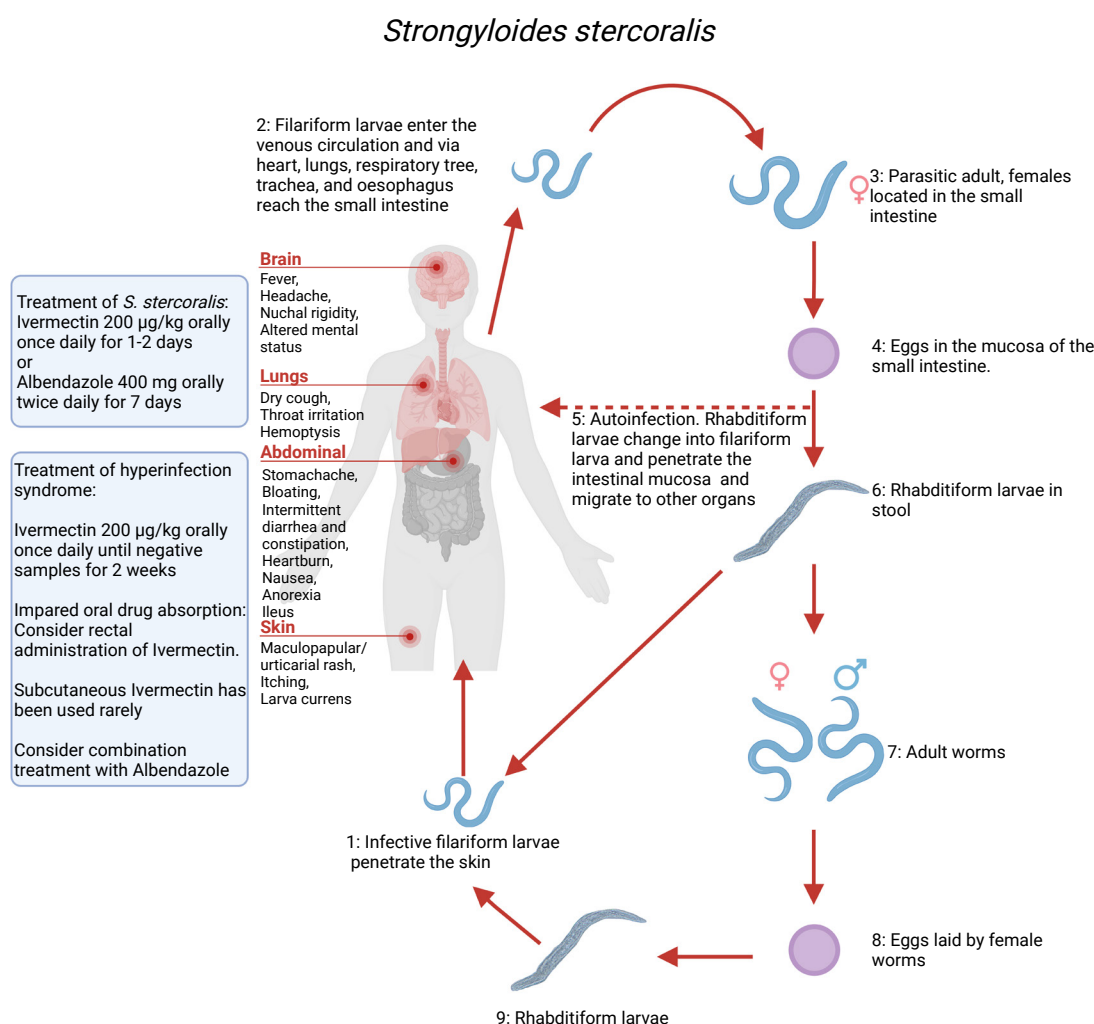


Figure 1 The lifecycle of *Strongyloides stercoralis*. 1: The infective filariform larvae begin the parasitic cycle by penetrating the skin. 2: The larvae migrate to the small intestine either via connective tissue, viscera or by migrating through lymphatic system to lungs, where they are coughed up and swallowed. 3 and 4: Female worms lay eggs in the mucosa of the small intestine. 5: Larvae penetrate from the intestinal mucosa and migrate to other organs causing autoinfection. 6: Rhabditiform larvae are excreted in the stool and either develop into infective filariform larvae (1) or enter the free-living cycle. 7: The larvae mature into adult worms. 8: The worms lay eggs, which hatch into rhabditiform larvae. 9: The larvae develop into infective filariform larvae, which can penetrate the skin.² The common symptoms of infection and treatment suggestions are provided on the left. Created with www.BioRender.com by AAP.

INVESTIGATIONS

CSF analyses with multiplex PCR in the FilmArray meningitis/encephalitis panel (BioFire Diagnostics, Salt Lake City, Utah, USA) were negative. Blood and CSF cultures were also negative. The patient was treated with benzylpenicillin, ceftriaxone and dexamethasone based on a presumptive clinical diagnosis of bacterial meningitis. A brain MRI scan showed a probable empyema in the right hemisphere. Stool samples were tested for pathogenic bacteria, virus and parasites. Microscopy of the stool revealed *S. stercoralis* rhabditiform larvae (figure 5). The blood eosinophil count continued to rise during the initial phase (figure 4). Analysis of bacterial, fungal and parasitic DNA (16S and 18S ribosomal RNA analysis) in the initial CSF sample revealed *S. stercoralis*-specific DNA.¹¹ This was confirmed by targeted real-time PCR-based detection of *S. stercoralis* DNA. Furthermore, the patient tested positive serologically with a strong anti-*Strongyloides* antibody reaction by an enzyme-linked

immunosorbent assay (*Strongyloides ratti* No. 9450, Bordier Affinity, Switzerland).

DIFFERENTIAL DIAGNOSIS

Comprehensive investigations during hospitalisation were carried out to rule out underlying malignancy, primary and secondary immunodeficiencies, rheumatological diseases and other infectious diseases. Tests included positron emission tomography-CT, and multiple CTs of the brain, thorax and abdomen, bone marrow microscopy, blood smear, immunoglobulins (IgA, IgM, IgG, IgG1, IgG2, IgG3, IgG4 and IgE), lymphocyte populations (CD19+, CD3+, CD4+, CD8+ and CD3-CD16/CD56+), M-protein, antinuclear antibodies, anti-neutrophil cytoplasmic antibodies and serology for human T-cell lymphotropic virus type 1 and 2, HIV, syphilis and viral hepatitis. The tests were unremarkable, except for a slightly elevated

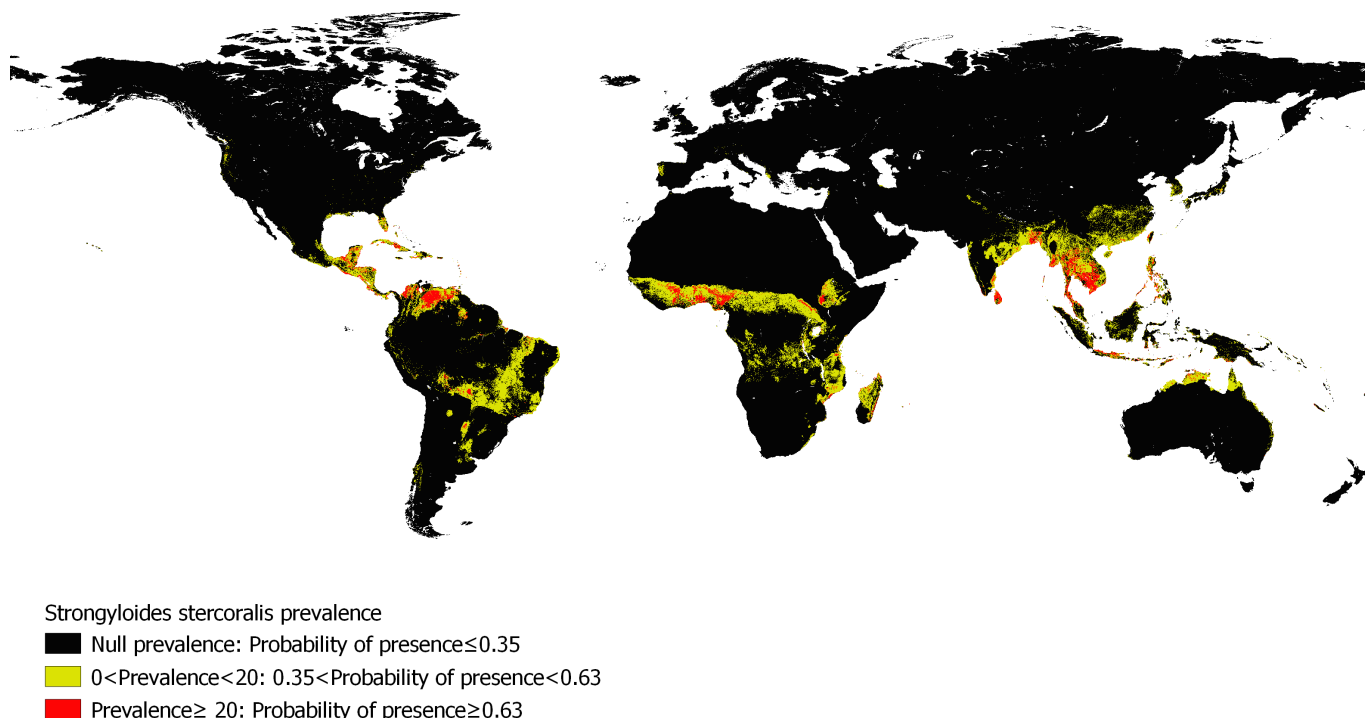


Figure 2 Map of the estimated prevalence of *Strongyloides stercoralis* as published in Fleitas *et al* CC BY 4.0.⁶

total IgG and a haemoglobin A1c (HbA1c) concentration of 70 mmol/mol (8.6%) with an average glucose level calculated at 10.9 mmol/L, which meets the diagnostic criteria for new-onset type 2 diabetes mellitus. However, the HbA1c was performed 11 days after administration of dexamethasone, which could have altered the HbA1c levels and thus the reliability of the diagnosis. The patient had no haemoglobinopathy and did not receive treatment with corticosteroids prior to admission.

TREATMENT

A diagnosis of *Strongyloides* hyperinfection with CNS involvement was made, and the patient was treated with oral ivermectin 200 µg/kg once daily for 37 days and albendazole 400 mg two times per day for 24 days. Rectal ivermectin and albendazole

equivalent to the oral dose were given initially during the first 16 days due to paralytic ileus and potentially impaired oral drug absorption in the intestinal tract.

OUTCOME AND FOLLOW-UP

Subsequent analysis of the CSF obtained 28 days after the initial lumbar puncture tested negative for both *Strongyloides*-specific real-time PCR and 16S and 18S ribosomal DNA analyses. *S. stercoralis* culture ('filter paper method') was used to evaluate treatment response, and no larvae were grown from the stool after treatment initiation.

The condition was complicated by *Klebsiella pneumoniae* sepsis, catheter-associated *Staphylococcus epidermidis* and *Staphylococcus haemolyticus* bacteraemia and a marked hypereosinophilia with a peak of $19.9 \times 10^9/\text{L}$ (figure 4).

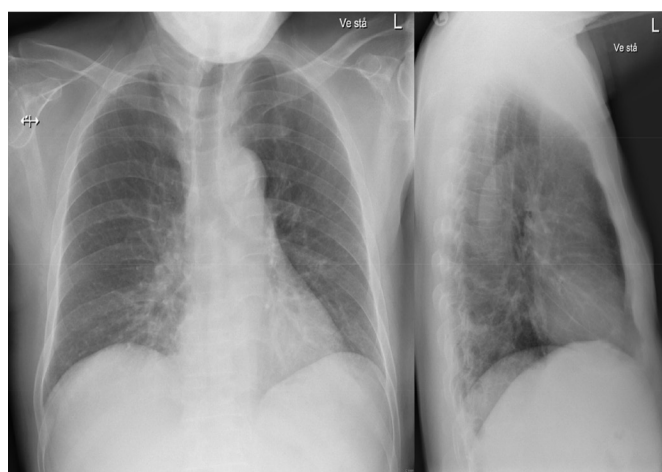

Figure 3 Thoracic X-ray at first admission. Anterior-posterior (left) and lateral view (right) showing bilateral basally located pneumonic infiltrates, most markedly on the right side. The patient was initially treated for pneumonia based on this presentation.

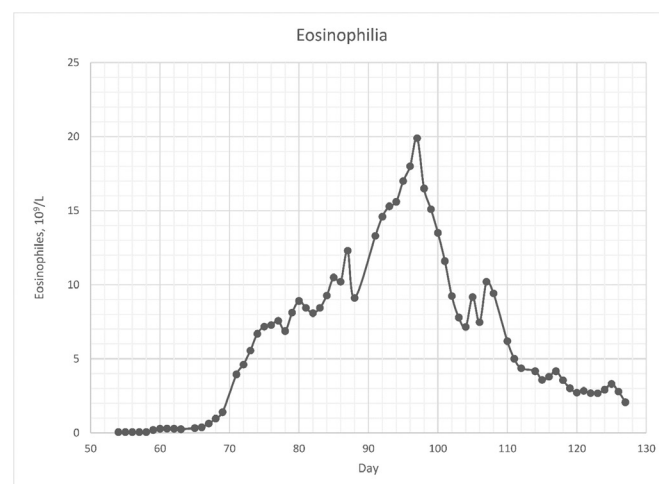


Figure 4 Time course of the blood concentration of eosinophils ($\times 10^9/\text{L}$). Graph created by AAP.

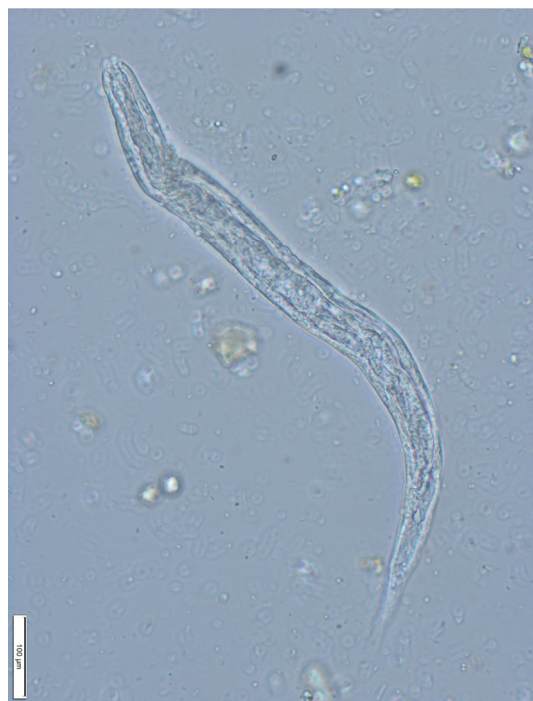

Figure 5 Filariform larvae of *Strongyloides stercoralis* observed by microscopy of a stool sample from the patient. The short buccal cavity characteristic of *S. stercoralis* is visible.

Unfortunately, the patient died from pulmonary oedema and pulmonary insufficiency 82 days after the last admission and 20 days after testing negative for *Strongyloides*-specific DNA in the CSF.

DISCUSSION

Strongyloides infection in the CNS has been reported previously, although almost exclusively in immunocompromised patients.^{12–17} *Strongyloides* seropositivity has been positively associated with diabetes, and few cases of disseminated strongyloidiasis associated with diabetes in the absence of any major immunodeficiency have been reported.^{7 18 19} On the

other hand, animal studies of helminth infections have shown a positive effect on glucose metabolism.²⁰ However, the ability to clear or control strongyloidiasis might be impaired in patients with type 2 diabetes.¹⁸ We present a case of CNS-involving strongyloidiasis in a patient with undiagnosed type 2 diabetes.

Strongyloides is prevalent in the tropics and subtropics, and even though the global prevalence is unknown, it is estimated that 30–100 million persons are infected worldwide.²

The seroprevalence in the adult population in regions of South East Asia is high (12.1%).^{5 21} However, the CNS manifestation of strongyloidiasis is extremely rare—even more so in non-endemic countries, where only eight antemortem cases have been documented.^{13 17 22–27} In the majority of cases, patients have a compromised immune system, for example, due to corticosteroid therapy, malignancy or chemotherapy. The prognosis of disseminated strongyloidiasis with CNS involvement is poor and associated with high mortality. Most cases of strongyloidiasis involving the CNS are diagnosed only on autopsy. Treatment of *S. stercoralis* infection is challenging due to the lack of sufficient evidence. Two doses of ivermectin 200 µg/kg orally 14 days apart have previously been recommended.²⁸ However, in uncomplicated infections, it is debated whether a single dose of ivermectin 200 µg/kg is as efficient as two or four doses of 200 µg/kg given on days 1, 2, 15 and 16.^{29 30} In hyperinfection/disseminated disease, ivermectin 200 µg/kg once daily continued for 14 days after the demonstration of negative stool samples for larvae has been suggested, often combined with empirical antibiotics targeting enteric pathogens.⁸ Alternatively, ivermectin can be combined with albendazole.^{29 31} A parenteral formulation of ivermectin for subcutaneous use in animals (Ivomec vet 1% injection) has been suggested for patients who do not tolerate oral therapy.^{8 32}

Treatment of CNS-involving strongyloidiasis still relies on limited evidence. In one case, successful treatment was achieved using 400 mg albendazole two times per day for 3 months.¹³ In another report, treatment with ivermectin 200 µg/kg once daily resulted in clearance of larvae from CSF; however, the patient died from cerebral damage.¹⁷ A combination of ivermectin and albendazole has also been used in two cases with favourable outcomes.¹² In our case, the patient achieved CSF clearance after combined treatment with ivermectin and albendazole, although he, unfortunately, died later in the course of hospitalisation due to respiratory insufficiency.

In conclusion, we report a case of *Strongyloides* hyperinfection presenting with pulmonary symptoms and meningitis in a South East Asian immunocompetent adult patient with type 2 diabetes. The patient was seen several times with pulmonary symptoms misdiagnosed as community-acquired pneumonia before he developed *Strongyloides*-induced meningitis. This case highlights the importance of a high degree of clinical suspicion required for the diagnosis of *Strongyloides* CNS infection in patients from endemic areas, owing to the high mortality. The disease should be suspected in patients from endemic areas who present with neurological and respiratory symptoms.

Contributors AAP and RMI conceptualised the report and collected clinical data. CRS was responsible for the PCR tests of *Strongyloides stercoralis*. GNH was responsible for the *S. stercoralis* microscopy. AAP drafted the manuscript. All authors critically revised the manuscript and approved the final version.

Funding The authors have not declared a specific grant for this research from any funding agency in the public, commercial or not-for-profit sectors.

Competing interests None declared.

Learning points

- ▶ *Strongyloides* can cause autoinfection (filariform larvae migrate from the large intestine to infect other organs) lasting for several years, and the disease is very common in the tropical and subtropical areas.
- ▶ *Strongyloides* hyperinfection often affects immunocompromised patients and can cause severe disease with high mortality.
- ▶ *Strongyloides* hyperinfection can manifest with symptoms corresponding to the affected organs, for example, fever, dry cough, throat irritation (lungs), stomachache, bloating, intermittent diarrhoea and constipation, heartburn, nausea, loss of appetite (gut), headache, nuchal rigidity and altered mental status (central nervous system).
- ▶ Treatment options include oral and/or rectal ivermectin and/or albendazole; however, the better choice is still debated.
- ▶ Diabetes may increase the risk of *Strongyloides* hyperinfection; however, the precise relationship between the two conditions is yet to be established.

Patient consent for publication Consent obtained from next of kin.

Provenance and peer review Not commissioned; externally peer reviewed.

Open access This is an open access article distributed in accordance with the Creative Commons Attribution Non Commercial (CC BY-NC 4.0) license, which permits others to distribute, remix, adapt, build upon this work non-commercially, and license their derivative works on different terms, provided the original work is properly cited and the use is non-commercial. See: <http://creativecommons.org/licenses/by-nc/4.0/>.

Case reports provide a valuable learning resource for the scientific community and can indicate areas of interest for future research. They should not be used in isolation to guide treatment choices or public health policy.

ORCID iDs

Andreas Arnholdt Pedersen <http://orcid.org/0000-0003-0751-6918>

Gitte Nyvang Hartmeyer <http://orcid.org/0000-0002-6786-3551>

Christen Rune Stensvold <http://orcid.org/0000-0002-1417-7048>

Raquel Martin-Iguacel <http://orcid.org/0000-0003-3543-1970>

REFERENCES

- Krolewiecki A, Nutman TB. Strongyloidiasis: a neglected tropical disease. *Infect Dis Clin North Am* 2019;33:135–51.
- CDC. Parasites - Strongyloides. Epidemiology & Risk Factors, 2018. Available: <https://www.cdc.gov/parasites/strongyloides/epi.html> [Accessed 28 Jul 2022].
- Schär F, Trostorf U, Giardina F, et al. Strongyloides stercoralis: global distribution and risk factors. *PLoS Negl Trop Dis* 2013;7:e2288.
- Asundi A, Beliavsky A, Liu XJ, et al. Prevalence of strongyloidiasis and schistosomiasis among migrants: a systematic review and meta-analysis. *Lancet Glob Health* 2019;7:e236–48.
- Diep NTN, Thai PQ, Trang NNM, et al. Strongyloides stercoralis seroprevalence in Vietnam. *Epidemiol Infect* 2017;145:3214–8.
- Fleitas PE, Kehl SD, Lopez W, et al. Mapping the global distribution of Strongyloides stercoralis and hookworms by ecological niche modeling. *Parasit Vectors* 2022;15:197.
- Lam CS, Tong MKH, Chan KM, et al. Disseminated strongyloidiasis: a retrospective study of clinical course and outcome. *Eur J Clin Microbiol Infect Dis* 2006;25:14–18.
- Mejia R, Nutman TB, Screening NTB. Screening, prevention, and treatment for Hyperinfection syndrome and disseminated infections caused by Strongyloides stercoralis. *Curr Opin Infect Dis* 2012;25:458–63.
- Pukkila-Worley R, Nardi V, Branda JA. Case records of the Massachusetts General Hospital. Case 28-2014. A 39-year-old man with a rash, headache, fever, nausea, and photophobia. *N Engl J Med* 2014;371:1051–60.
- Olsen A, van Lieshout L, Marti H, et al. Strongyloidiasis--the most neglected of the neglected tropical diseases? *Trans R Soc Trop Med Hyg* 2009;103:967–72.
- Krogsgaard LR, Andersen Lee O 'Brien, Johannesen TB, et al. Characteristics of the bacterial microbiome in association with common intestinal parasites in irritable bowel syndrome. *Clin Transl Gastroenterol* 2018;9:161.
- Sebastian IA, Pandian JD, Oberoi A, et al. Disseminated strongyloidiasis: breaking brain barriers. *Ann Indian Acad Neurol* 2019;22:234–7.
- Oktar N, Ozer H, Demirtas E. Central nervous system Strongyloides stercoralis. A case report. *Turk Neurosurg* 2018.
- Reyes F, Singh N, Anjuman-Khurram N, et al. Strongyloides hyperinfection syndrome causing fatal meningitis and septicemia by Citrobacter koseri. *IDCases* 2017;10:102–4.
- Nadir E, Grossman T, Ciobotaro P, et al. Real-Time PCR for Strongyloides stercoralis-associated meningitis. *Diagn Microbiol Infect Dis* 2016;84:197–9.
- Pypen Y, Oris E, Meeuwissen J, et al. Late onset of Strongyloides stercoralis meningitis in a retired Belgian miner. *Acta Clin Belg* 2015;70:447–50.
- Dokmeci O, Forshay B, Scholand SJ. Worms on the brain: fatal meningoencephalitis from disseminated Strongyloides infection. *Conn Med* 2013;77:31–3.
- McGuire E, Welch C, Melzer M. Is Strongyloides seropositivity associated with diabetes mellitus? A retrospective case-control study in an East London NHS Trust. *Trans R Soc Trop Med Hyg* 2019;113:189–94.
- Murali A, Rajendiran G, Ranganathan K, et al. Disseminated infection with Strongyloides stercoralis in a diabetic patient. *Indian J Med Microbiol* 2010;28:407–8.
- Pace F, Carvalho BM, Zanotto TM, et al. Helminth infection in mice improves insulin sensitivity via modulation of gut microbiota and fatty acid metabolism. *Pharmacol Res* 2018;132:33–46.
- Buonfrate D, Bisanzio D, Giorli G, et al. The Global Prevalence of Strongyloides stercoralis Infection. *Pathogens* 2020;9:468.
- Tam J, Schwartz KL, Keystone J, et al. Case report: central nervous system strongyloidiasis: two cases diagnosed antemortem. *Am J Trop Med Hyg* 2019;100:130–4.
- Comelli A, Mangioni D, Scaramella L, et al. Strongyloides stercoralis central nervous system dissemination in a migrant misdiagnosed with eosinophilic granulomatosis with polyangiitis. *J Travel Med* 2022;29. doi:10.1093/jtm/taab177. [Epub ahead of print: 17 Jan 2022].
- Bradley SL, Dines DE, Brewer NS. Disseminated Strongyloides stercoralis in an immunosuppressed host. *Mayo Clin Proc* 1978;53:332–5.
- Meltzer RS, Singer C, Armstrong D, et al. Case report: antemortem diagnosis of central nervous system strongyloidiasis. *Am J Med Sci* 1979;277:91–8.
- Belani A, Leprone D, Shands JW. Strongyloides meningitis. *South Med J* 1987;80:916–8.
- Dutcher JP, Marcus SL, Tanowitz HB, et al. Disseminated strongyloidiasis with central nervous system involvement diagnosed antemortem in a patient with acquired immunodeficiency syndrome and Burkitts lymphoma. *Cancer* 1990;66:2417–20.
- Woll F, Gotuzzo E, Montes M. Strongyloides stercoralis infection complicating the central nervous system. *Handb Clin Neurol* 2013;114:229–34.
- Buonfrate D, Salas-Coronas J, Muñoz J, et al. Multiple-Dose versus single-dose ivermectin for Strongyloides stercoralis infection (strong treat 1 to 4): a multicentre, open-label, phase 3, randomised controlled superiority trial. *Lancet Infect Dis* 2019;19:1181–90.
- Repetto SA, Ruybal P, Batalla E, et al. Strongyloidiasis outside endemic areas: long-term parasitological and clinical follow-up after ivermectin treatment. *Clin Infect Dis* 2018;66:1558–65.
- Teixeira MCA, Pacheco FTF, Souza JN, et al. Strongyloides stercoralis Infection in Alcoholic Patients. *Biomed Res Int* 2016;2016:1–11.
- Marty FM, Lowry CM, Rodriguez M, et al. Treatment of human disseminated strongyloidiasis with a parenteral veterinary formulation of ivermectin. *Clin Infect Dis* 2005;41:e5–8.

Copyright 2022 BMJ Publishing Group. All rights reserved. For permission to reuse any of this content visit <https://www.bmj.com/company/products-services/rights-and-licensing/permissions/>
BMJ Case Report Fellows may re-use this article for personal use and teaching without any further permission.

Become a Fellow of BMJ Case Reports today and you can:

- ▶ Submit as many cases as you like
- ▶ Enjoy fast sympathetic peer review and rapid publication of accepted articles
- ▶ Access all the published articles
- ▶ Re-use any of the published material for personal use and teaching without further permission

Customer Service

If you have any further queries about your subscription, please contact our customer services team on +44 (0) 207111 1105 or via email at support@bmj.com.

Visit casereports.bmj.com for more articles like this and to become a Fellow