

# Small intestine enterostomy for the intraoperative delivery of levodopa in a patient with severe Parkinson's disease

Jasun Li,<sup>1</sup> Daniel R A Cox,<sup>2</sup> Vijayaragavan Muralidharan,<sup>2</sup> Laurence Weinberg <sup>1,2</sup>

<sup>1</sup>Department of Anaesthesia, Austin Health, Heidelberg, Victoria, Australia

<sup>2</sup>The University of Melbourne Department of Surgery, Austin Health, Melbourne, Victoria, Australia

## Correspondence to

Professor Laurence Weinberg; laurence.weinberg@austin.org.au

Accepted 21 November 2020

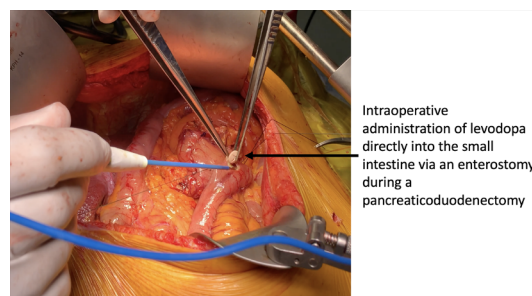
## DESCRIPTION

The intraoperative delivery of medications for patients with Parkinson's disease (PD) during prolonged surgery is challenging. In complex surgical procedures, PD medications are commonly delivered via a nasogastric tube. However, this technique is not feasible in procedures where the stomach is divided or disconnected proximal to the pylorus. Because levodopa—the first line treatment for PD—is absorbed from the proximal small bowel,<sup>1</sup> it is ineffective when administered as a suppository. Failure to administer PD medication into the proximal small bowel in these situations can disrupt dosing and delivery of PD medications. In turn, this can exacerbate PD symptoms in the perioperative timeframe; intraoperative tremor and rigidity<sup>2</sup> and postoperative neuroleptic malignant syndrome have been reported.<sup>3</sup>

Parenteral delivery of PD medications such as diphenhydramine and benztropine have been described; however, these therapies may be inadequate in treating advanced PD. While subcutaneous apomorphine and rotigotine patches can be used, the former can be severely emetogenic and cause hallucinations, and the latter may be unable to deliver sufficiently high doses of medication required by patients with severe PD.<sup>4</sup> The use of the intravenous dopamine agonist lisuride is well described, however is not available in many countries.

We describe a simple, effective and pragmatic intraoperative strategy to reliably deliver PD medications in patients with severe PD who are undergoing surgery where delivery of PD medications via nasogastric tube is contraindicated. An 81-year-old man with a 9-year history of severe PD was admitted to our institution for curative ampullary adenocarcinoma resection via standard pancreaticoduodenectomy. His PD was managed with oral levodopa-benserazide 100 mg–25 mg taken three times per day. Intraoperatively, at four hourly intervals, a small enterostomy was made in the small intestine at the prospective site of the gastrojejunostomy (figure 1). The medication was carefully delivered directly into the small intestine lumen using forceps, under vision, via this enterostomy and milked distally (figure 1, video 1).

The enterostomy was later extended longitudinally to approximately 6 cm and a gastrojejunostomy was fashioned as per usual practice to complete

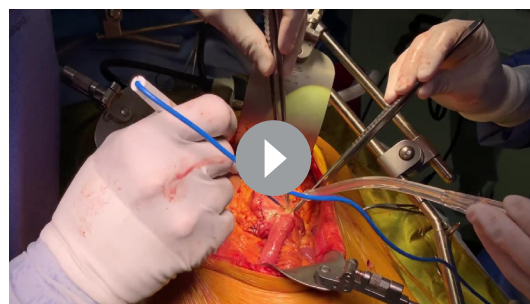


**Figure 1** Intraoperative administration of levodopa via a small intestine enterostomy.

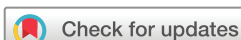a Roux-en-Y reconstruction. The standard practice by the authors is a retrocolic, posterior, side-to-side gastroenterostomy where the anastomosis is positioned in the infracolic space. The naso-gastric tube, which was inserted at the beginning of the procedure was removed after extubation, and the patient was commenced on oral fluids as tolerated according to ERAS protocols.<sup>5</sup> At our institution, the 5-year cumulative incidence of delayed gastric emptying grades B and C is 0.2% (International Study Group of Pancreatic Surgery definition<sup>6</sup>).

The patient displayed no motor symptom fluctuations, and was mobile and ambulatory within six postoperative hours. All PD medications were then delivered via the enteral route. The patient made an uneventful recovery and was discharge home at postoperative day 8.

In summary, delivering oral PD medication via a small intestine enterostomy as described in this case can be practical during certain major surgical procedures. This technique allows accurate timing of PD medication administration, enabling tighter adherence to patients' typical medication dosing



**Video 1** Intraoperative technique demonstrating the administration of levodopa via a small intestine enterostomy



© BMJ Publishing Group Limited 2020. No commercial re-use. See rights and permissions. Published by BMJ.

**To cite:** Li J, Cox DRA, Muralidharan V, et al. *BMJ Case Rep* 2020;**13**:e240367. doi:10.1136/bcr-2020-240367

## Learning points

- Perioperative delivery of levodopa is paramount in patients with Parkinson's disease (PD). Failure to administer levodopa can result in generalised tremor, rigidity and neuroleptic malignant syndrome.
- In procedures where the stomach is disconnected from the distal gastrointestinal (GI) tract, the delivery of levodopa via a nasogastric tube is not feasible.
- Intraoperative administration of levodopa via a small intestine enterostomy is a simple, effective, and pragmatic intraoperative strategy for delivery of PD medication for patients undergoing gastrointestinal surgery

regimens perioperatively, and facilitates enhanced recovery after major abdominal surgery.

**Contributors** LW: principle anaesthetist caring for the patient, responsible for literature review, collation of images, preparation of video and writing of manuscript. VM: principle surgeon caring for patient, responsible for writing of manuscript. DRAC: assistant surgeon caring for patient, responsible for writing of manuscript. JL: medical student/incoming junior doctor assisting with literature review, preparation of images and video and writing of manuscript.

**Funding** The authors have not declared a specific grant for this research from any funding agency in the public, commercial or not-for-profit sectors.

**Competing interests** None declared.

**Patient consent for publication** Obtained.

**Provenance and peer review** Not commissioned; externally peer reviewed.

**ORCID iD**

Laurence Weinberg <http://orcid.org/0000-0001-7403-7680>

**REFERENCES**

- 1 Kurlan R, Nutt JG, Woodward WR, *et al.* Duodenal and gastric delivery of levodopa in parkinsonism. *Ann Neurol* 1988;23:589–95.
- 2 Reed AP, Han DG. Intraoperative exacerbation of Parkinson's disease. *Anesth Analg* 1992;75:850–3.
- 3 Stotz M, Thümmel D, Schürch M, *et al.* Fulminant neuroleptic malignant syndrome after perioperative withdrawal of antiParkinsonian medication. *Br J Anaesth* 2004;93:868–71.
- 4 Brennan KA, Genever RW. Managing Parkinson's disease during surgery. *BMJ* 2010;341:c5718.
- 5 Melloul E, Lassen K, Roulin D, *et al.* Guidelines for perioperative care for pancreatoduodenectomy: enhanced recovery after surgery (ERAS) recommendations 2019. *World J Surg* 2020;44:2056–84.
- 6 Wente MN, Bassi C, Dervenis C, *et al.* Delayed gastric emptying (DGE) after pancreatic surgery: a suggested definition by the International Study group of pancreatic surgery (ISGPS). *Surgery* 2007;142:761–8.

Copyright 2020 BMJ Publishing Group. All rights reserved. For permission to reuse any of this content visit <https://www.bmj.com/company/products-services/rights-and-licensing/permissions/>  
BMJ Case Report Fellows may re-use this article for personal use and teaching without any further permission.

Become a Fellow of BMJ Case Reports today and you can:

- Submit as many cases as you like
- Enjoy fast sympathetic peer review and rapid publication of accepted articles
- Access all the published articles
- Re-use any of the published material for personal use and teaching without further permission

**Customer Service**

If you have any further queries about your subscription, please contact our customer services team on +44 (0) 207111 1105 or via email at [support@bmj.com](mailto:support@bmj.com).

Visit [casereports.bmj.com](http://casereports.bmj.com) for more articles like this and to become a Fellow